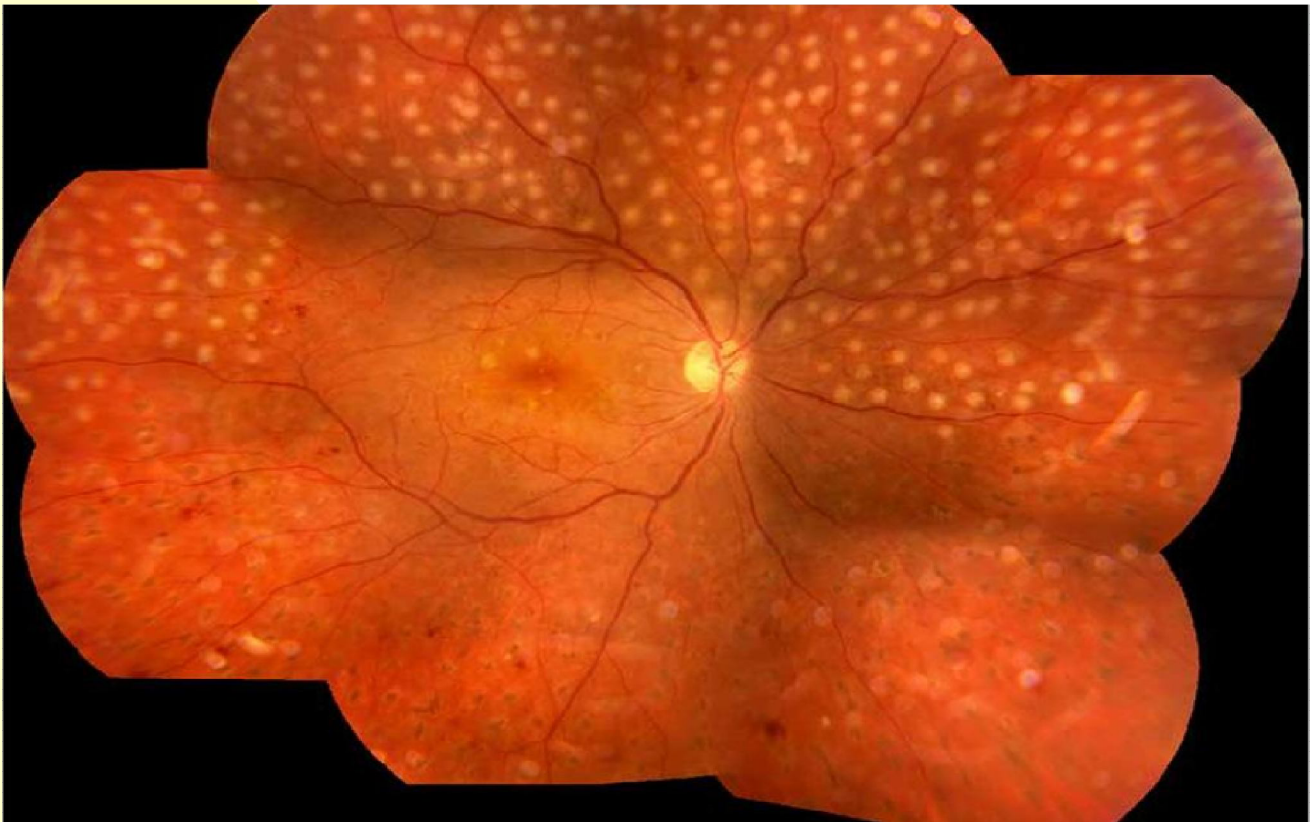



INTERNATIONAL COUNCIL
of OPHTHALMOLOGY



Guidelines for **Diabetic Eye Care in India**

January 2015

Adapted from guidelines formed by International Council of Ophthalmology

VISION 2020: The Right to Sight – INDIA

Preface

Diabetic retinopathy, one of the complications of diabetes (others being vascular disease, renal failure and leg amputation) is an important cause of avoidable blindness globally. The risk of diabetic retinopathy (DR) increases with increasing duration of diabetes and poor control of blood glucose, cholesterol and high blood pressure. DR cannot be entirely prevented, but the severe stages which are sight threatening can be reduced by improved control of risk factors. Visual loss can be controlled by early detection and treatment (i.e. laser treatment and/or injection of agents into the eye).

The number of people with diabetes is increasing globally. In India, it is estimated that there are 65.1 million people with diabetes and another 21.5 million in the pre-diabetes stage (i.e. at very high risk). The number of people with diabetics is projected to increase to 109 million by 2035. These data suggest that there is a need to expand services for diabetes to rural areas and to develop and implement appropriate prevention and control interventions.

While community interventions can be planned and implemented to ensure access to services, standard protocols are indispensable for program managers and Ophthalmologists to ensure quality treatment of DR in a uniform manner across the country. Absence of such guidelines pose a critical challenge for all those involved in DR management. In view of the commitment from the government and readiness of the civil society institutions to scale-up DR management and improve its quality treatment across the country, VISION 2020: The Right to Sight – India took the lead to review currently available tools. No guidelines are found to be available for India. Fortunately, there exist guidelines developed by International Council of Ophthalmology (ICO) in 2014.

VISION 2020: The Right to Sight -INDIA held a consultation on possible adaptation of ICO guidelines in Indian context with the active participation of institutions and experts working in DR management in the country. Suggestions and inputs have been sought and incorporated to set guidelines in the national context based in their practical experience of both Diabetic retinopathy management and community programs. Before its final adaptation at national level, VISION 2020 India strongly feels the need of testing the guidelines among its partner institutions and other agencies interested for a considerable time period. Further consultations will be held to take in the e feedback from implementation of the present guidelines, and develop final guidelines.

Orbis India provided financial support for the consultation. Divyajyoti Trust led the process and played an active role to make the consultation a huge success.

Dr. Sara Varughese
President

VISION 2020: RIGHT TO SIGHT - INDIA *Guidelines for Diabetic Eye Care*

VISION 2020: RIGHT TO SIGHT-INDIA developed the *Vision 2020: Right to Sight India Guidelines for Diabetic Eye Care* to serve a supportive and educational role for ophthalmologists and eye care providers adapting the ICO guideline. They are intended to improve the quality of eye care for patients around the country.

The *Guidelines* are designed to inform ophthalmologists about the requirements for the screening and detection of diabetic retinopathy, and the appropriate assessment and management of patients with diabetic retinopathy. The *Guidelines* also demonstrate the need for ophthalmologists to work with primary care providers and appropriate specialists such as endocrinologists.

With diabetes and diabetic retinopathy a rapidly increasing problem worldwide, it is vital to ensure that ophthalmologists and eye care providers are adequately prepared.

The VISION 2020: RIGHT TO SIGHT-INDIA believes an ethical approach is indispensable, as it is the first step toward quality clinical practices.

The *Guidelines* are designed to be a working document and will be updated on an ongoing basis. They are first released in January 2015. This document is adapted from ICO guidelines (February 2014) on the same subject.

Please email us at: info@vision2020india.org

ICO Task Force (2013) and Eye Care Committee (2014):

2013 ICO Task Force on Diabetic Eye Care	2014 ICO Diabetic Eye Care Committee
<ul style="list-style-type: none">• Hugh Taylor, MD, AC, Chairman	<ul style="list-style-type: none">• Tien Yin Wong, MD, MBBS, PhD, Chairman
<ul style="list-style-type: none">• Susanne Binder, MD	<ul style="list-style-type: none">• Rick Ferris, MD
<ul style="list-style-type: none">• Taraprasad Das, MD, FRCS	<ul style="list-style-type: none">• Neeru Gupta, MD, PhD, MBA
<ul style="list-style-type: none">• Michel Farah, MD	<ul style="list-style-type: none">• Van Lansingh, MD, PhD
<ul style="list-style-type: none">• Frederick Ferris, MD	<ul style="list-style-type: none">• Wanjiku Mathenge, MD, PhD, MBChB
<ul style="list-style-type: none">• Pascale Massin, MD, PhD, MBA	<ul style="list-style-type: none">• Eduardo Mayorga, MD
<ul style="list-style-type: none">• Wanjiku Mathenge, MD, PhD, MBChB	<ul style="list-style-type: none">• Sunil Moreker, MBBS
<ul style="list-style-type: none">• Serge Resnikoff, MD, PhD	<ul style="list-style-type: none">• Serge Resnikoff, MD, PhD
<ul style="list-style-type: none">• Bruce E. Spivey, MD, MS, MEd	<ul style="list-style-type: none">• Hugh Taylor, MD, AC
<ul style="list-style-type: none">• Juan Verdager, MD	<ul style="list-style-type: none">• Juan Verdager, MD
<ul style="list-style-type: none">• Tien Yin Wong, MD, PhD	
<ul style="list-style-type: none">• Peiquan Zhao, MD	

For non-commercial use

VISION 2020: The Right to Sight-INDIA: December 2014 Diabetic Retinopathy consultative meeting

• Dr. P. N. Nagpal	• Dr. Vishwanath
• Dr. Padmaja Kumari	• Dr. Anand Rajendran
• Dr. Rajiv Raman	• Dr. Sucheta Kulkarni
• Dr. Manisha Agrawal	• Dr. Abhishek Dagar
• Dr. Thomas Cherian	• Dr. Mahesh Shanmugam
• Dr. Alok Sen	• Dr. Shoumya Jyoti Dutta Mazumder
• Dr. M Prathibha	• Dr. Renu Dhasmana
• Dr. Sunita Mohan	• Dr Kamlesh Khilnani
• Dr. Sumeet Khanduja	• Dr. Jennifer Basaiwamoit
• Dr. GVS Murthy	• Dr. Praveen Vashist
• Dr. Sandeep Bhuttan	• Dr. Rahul Ali
• Dr. Surendranath Reddy	• Mr. Ajit Bhardwaj
• Dr. Mansi Krishnani	• Dr. Abhishek Agrawal
• Dr. Shashi Sharma	• Mr. Manish Kumar
• Dr. Uday Gajiwala	• Dr. Rohan Chariwala

For non-commercial use

Index

	Page No.
I. Introduction	6-8
II. Screening Guidelines	9-10
III. Detailed Ophthalmic Assessment of Diabetic Retinopathy	10-12
IV. Treatment of Diabetic Retinopathy	12-16
Annexes	16-37
Credit	38
Acknowledgements	38

I. Introduction

Diabetes mellitus (DM) is a global epidemic with significant morbidity. Diabetic retinopathy (DR) is the specific micro vascular complication of DM and affects 1 in 3 persons with DM. DR remains a leading cause of vision loss in working adult populations. Patients with severe levels of DR are reported to have poorer quality of life and reduced levels of physical, emotional and social well-being and they utilize more health care resources.

Epidemiological studies and clinical trials have shown that optimal control of blood glucose, blood pressure and blood lipids, Hemoglobin can reduce the risk of developing retinopathy and slow its progression. Timely treatment with laser photocoagulation and increasingly, the appropriate use of intraocular administration of vascular endothelial growth factor (VEGF) inhibitors can prevent visual loss in vision-threatening retinopathy, particularly diabetic macular oedema (DME). Since visual loss may not be present in the earlier stages of retinopathy, regular screening of persons with diabetes is essential to enable early intervention.

Global Epidemiology of Diabetic Retinopathy

In many countries, DR is the most frequent cause of preventable blindness in working-aged adults. In the United States, an estimated 40% (8% for vision-threatening retinopathy) of persons with type 2 diabetes and 86% (42% for vision-threatening retinopathy) of persons with type 1 diabetes have DR. High prevalence estimates have also been reported in other countries. Despite concern about a potential diabetes epidemic in Asia, epidemiologic data for DR in Asian countries is relatively limited. In Latin America, 40% of diabetic patients had some DR and 17% required treatment. Few studies of DR have been conducted in Africa.

Epidemiology of Diabetic Retinopathy in India

Diabetes is growing alarmingly in India, home to more than 65.1 million people with the disease, compared to 50.8 million in 2010.¹ Indian Council of Medical Research-India Diabetes (ICMR-INDIAB) study covering 3 states (Tamil Nadu, Maharashtra and Jharkhand) and 1 union territory (Chandigarh) states the prevalence of Diabetes ranging from 10.4% - 13.6% and prevalence of Prediabetes (Impaired Fasting Glucose and/or Impaired glucose tolerance) was between 8-14.6%.² Along with the rise in Diabetes prevalence, there is also an alarming rise in the prevalence of Diabetic retinopathy (DR) in both urban and rural India. Epidemiological data from India suggests the prevalence of DR is 18% in the urban and 10.4% in the rural India.³⁻⁴ It means DR is found in every 5th person with diabetes in the urban and in every 10th person with diabetes in the rural areas of India.

1. International Diabetes Federation Diabetes Atlas, 6th edition 2013
2. Anjana RM, Pradeepa R, Deepa M, Mohan V et al ICMR-INDIAB Collaborative Study Group. Prevalence of diabetes and prediabetes (impaired fasting glucose and/or impaired glucose tolerance) in urban and rural India: phase I results of the Indian Council of Medical Research-India Diabetes (ICMR-INDIAB) study. *Diabetologia*. 2011 Dec;54(12):3022-7.
3. Raman R¹, Rani PK, Reddi Racheppalle S, Gnanamoorthy P, Uthra S, Kumaramanickavel G, Sharma T. Prevalence of diabetic retinopathy in India: Sankara Nethralaya Diabetic Retinopathy Epidemiology and Molecular Genetics Study report 2. *Ophthalmology*. 2009 Feb;116(2):311-8.
4. Raman R, Ganesan S, Pal SS, Kulothungan V, Sharma T. Prevalence and risk factors for diabetic retinopathy in rural India. Sankara Nethralaya Diabetic Retinopathy Epidemiology and Molecular Genetic Study III (SN-DREAMS III), report no 2. *BMJ Open Diabetes Res Care*. 2014 Jun 6;2

DR develops with time and is associated with poor control of blood sugar, blood pressure and blood lipids. The

For non-commercial use

longer someone has had DM and the poorer their control, the higher their risk of developing DR. Good control reduces the annual incidence of developing DR and extends life. However, good control does not necessarily reduce the lifetime risk of developing DR, so everyone with DM is at risk.

The overall prevalence of DR in a community is also influenced by the number of people diagnosed with early DM:

- In resource-rich settings with good health care systems, more people with early DM will have been diagnosed. The prevalence of DR in people with newly diagnosed DM will be low, resulting in a lower overall prevalence of DR.
- In resource-poor settings with less advanced health care systems, fewer people with early DM will have been diagnosed. People may be diagnosed with diabetes only when symptomatic or complications have occurred. Thus, the prevalence of DR in people with newly diagnosed DM will be high, resulting in a somewhat higher overall prevalence of DR.

In general, meta-analysis of large scale studies show that approximately one third of those with DM will have DR and approximately one third of those (or 10% of persons with DM) will have vision-threatening DR that requires treatment.

Classification of Diabetic Retinopathy

The classic retinal micro vascular signs of DR include micro aneurysms, haemorrhages, hard exudates (lipid deposits), cotton-wool spots (ischemic retina related to accumulations of axoplasmic debris within adjacent bundles of ganglion cell axons), venous dilation and beading and intra retinal micro vascular abnormalities (i.e., dilated pre-existing capillaries). (**Annex Figures**). These signs can be classified into two phases of DR.

Non-proliferative Diabetic Retinopathy

Non proliferative DR is the early stage of DR. Recognition of non-proliferative retinopathy allows a prediction of risk of progression, visual loss and determination of a review interval. **Annex Table 1** shows the signs of non-proliferative DR.

Proliferative Diabetic Retinopathy

Proliferative diabetic retinopathy (PDR) is a severe stage of DR and represents an angiogenic response of the retina to extensive ischemia and capillary closure. Neovascularization has been divided into 2 groups: new vessels on the disc (NVD) and new vessels elsewhere (NVE). Typically NVE grow at the interface of perfused and non-perfused retina. **Annex Table 2** shows the signs of PDR.

The stages of DR, from non-proliferative to proliferative DR, can be classified using the simple international classification of DR scale shown in **Table 1**. DME is an important complication that is assessed separately from the stages of retinopathy, as it can be associated with any of the DR stages and can run an independent course.

Diabetic Macular Oedema

It is important to assess the presence and severity of diabetic macular oedema (DME) separately from stages of DR.

The stages of DR can be classified using the International Classification of DR Scale shown in **Table 1**. A simplified grading based on this with referral decision can be used in low-resource settings (**Table 2**). It is important to remember that early DME may be first detected by a reduction in visual acuity. An online self-directed course on the grading of diabetic retinopathy is available at: drgrading.iehu.unimelb.edu.au.

Table 1 and 2: Indian Classification of Diabetic Retinopathy and Diabetic Macular Oedema and Referral Recommendations.

Table 1

Diabetic Retinopathy	Findings Observable on Dilated Ophthalmoscopy	Referral*
No apparent retinopathy	No abnormalities	Review in 1 year
Mild non proliferative DR	Micro aneurysms only	Review in 1 year
Moderate non proliferative diabetic retinopathy	More than just micro aneurysms, but less than severe non proliferative DR	Review in 6 months or refer to ophthalmologist
Severe non-proliferative DR	Any of the following: <ul style="list-style-type: none"> • Intra-retinal haemorrhages (≥ 20 in each quadrant); • Definite venous beading (in 2 quadrants); • Intra retinal micro vascular abnormalities (in 1 quadrant); and • no signs of proliferative retinopathy 	Refer to retinologist
Proliferative DR	Severe non proliferative DR and 1 or more of the following: <ul style="list-style-type: none"> • Neovascularization • Vitreous/ pre retinal haemorrhage 	Refer to retinologist

Table 2

Diabetic Macular Oedema	Findings Observable on Dilated Ophthalmoscopy [#]	Referral*
DME absent	No retinal thickening or hard exudates in posterior pole	Review in 1 year
DME present	Retinal thickening or hard exudates in posterior pole	Refer to retinologist
Mild DME	Retinal thickening or hard exudates in posterior pole but outside the central subfield of the macula (diameter 1000 μm)	Refer to retinologist
Moderate DME	Retinal thickening or hard exudates within the central subfield of the macula but not involving the centre point	Refer to retinologist
Severe DME	Retinal thickening or hard exudates involving the centre of the macula	Refer to retinologist

* For Non-Ophthalmologist any DR should be referred to Ophthalmologist.

[#] Hard exudates are a sign of current or previous macular oedema. DME is defined as retinal thickening and this requires a three-dimensional assessment that is best performed by a dilated examination using slit-lamp bio microscopy and/ or stereo fundus photography.

II. Screening Guidelines

Screening Guidelines

Screening for DR is an important aspect of DM management worldwide.

A screening exam could include a complete ophthalmic examination with refracted visual acuity fundus photography. However, in a low-resource setting, the minimum examination components to assure appropriate referral should include a screening visual acuity exam and retinal examination adequate for DR classification. Vision should be tested prior to pupil dilation. **Annex Figure 1** shows an example of the screening process for DR.

Who should screen?

1. Ophthalmologist
2. Physician
3. Optometrist/ Ophthalmic assistant: Who have skill of screening of DR learnt either during his training or after training by a doctor engaged in screening.
4. Any field level worker or health volunteer: Who either had training in grading images at any institution or has been trained with doctor engaged in active screening for at least 3 months.

How to screen?

1. Indirect Ophthalmoscopy
2. Slit-lamp bio microscopic examination
3. Dilated Direct Ophthalmoscopy
4. Non-Mydriatic photography
5. Mydriatic photography
6. Hand held fundus cameras

The screening vision exam should be completed by trained personnel in any of the following ways, depending on resources:

- Refracted visual acuity examination using a 3- or 4-meter visual acuity lane and a high contrast visual acuity chart.
- Presenting visual acuity examination using a near or distance eye chart and a pin-hole option if visual acuity is reduced.
- Presenting visual acuity examination using a 6/12 (20/40) equivalent handheld chart consisting of at least 5 standard letters or symbols and a pin-hole option if visual acuity is reduced.

A retinal examination may be accomplished in the following ways:

- Direct or indirect ophthalmoscopy or slit-lamp bio microscopic examination of the retina.
- Retinal (fundus) photography (including any of the following: wide field to 30°; mono- or stereo-; dilated or undilated). (Annex Table 3). This could also include telemedicine approaches.
- For the retinal examination, a medical degree may not be necessary, but the examiner must be well trained to perform ophthalmoscopy or retinal photography and be able to assess the severity of DR.

Using adequate information from the visual acuity and retinal examinations, one can decide on an appropriate

management plan, as outlined in **Table 2**. The plan may be modified based on individual patient requirements.

Patients with less than adequate retinal assessment should be referred to an ophthalmologist unless it is obvious that there is no DR, or at the most, only mild non-proliferative DR (i.e., micro aneurysms only). In addition, persons with unexplained visual-acuity loss should be referred.

As part of a screening exam, persons with diabetes should be asked about their diabetes control, including blood glucose, blood pressure and serum lipids. In addition, women should be asked if they are or could be pregnant. Inadequate control and pregnancy may require further appropriate medical intervention. Doctor also should adopt holistic approach for the Diabetic patients and instruct nurses, dieticians, counsellors and other cadres to take care of other diabetes related complications as well.

Whom to screen?

- People with known diabetes. For screening DR, it is not cost effective to first screen for Diabetes and then retinopathy.
- Opportunistic screening: Screening for DR in all patients attending an eye clinic
- Mass screening: Having specific camps for DR screening as an outreach activity in individuals having 2 hour-post prandial Glucose (PP2BS) >140 mg/dl or fasting blood sugar (FBS) >110 mg/dl.

Referral Guidelines

Minimum referral guidelines are as follows:

- Visual acuity below 6/12 (20/40) or symptomatic vision complaints. [Note: While using telemedicine approach Visual acuity is not mandatory]
- If DR can be classified according to the International Classification of DR or a Simplified scheme, they should be referred accordingly (Table 1 and 2)
- If retinal exam or retinal imaging is available but only a less detailed classification of DR is possible:
 - »» No retinopathy or only a few small red spots: return for screening exam in 1 year
 - »» Dot or blot haemorrhages or possible neovascularization: refer to ophthalmologist
 - »» White spots in the retina: refer to ophthalmologist
- If visual acuity or retinal examination cannot be obtained at the screening examination: refer to ophthalmologist
- Patients who have had laser treatment should also be referred for ophthalmic review

III. Detailed Ophthalmic Assessment of Diabetic Retinopathy

1. Initial Patient Assessment

Detailed patient assessment should include a complete ophthalmic examination, including visual acuity and the identification and grading of severity of DR and presence of DME for each eye. The patient assessment should also include the taking of a patient history focused on diabetes and its modifiers.

a. Patient History (Key Elements)

- Duration of diabetes
- Past glycemic control (hemoglobin A1c)
- Medications (especially insulin, oral hypoglycemics, anti hypertensives, and lipid-lowering drugs)

For non-commercial use

- Systemic history (e.g., renal disease, systemic hypertension, serum lipid levels, pregnancy)
- Ocular history

b. Initial Physical Exam (Key Elements)

- Visual acuity
- Measurement of intraocular pressure (IOP)
- Gonioscopy when indicated (e.g., when neovascularization of the iris is seen or in eyes with increased IOP)
- Slit-lamp bio microscopy
- Fundus examination

c. Fundus Examination Assessment Methods

Currently, the two most sensitive methods for detecting DR are retinal photography and slit-lamp bio microscopy through dilated pupils. Both depend on interpretation by trained eye health professionals. Other methods are listed in **Annex Table 2**.

Fundus photography has the advantage of creating a permanent record and for that reason, it is the preferred method for retinopathy assessment. However, ophthalmologists/ retinologists can identify DR without photography and documentation of an observation in form of diagram in absence of Fundus photograph can be done but in hands of non-ophthalmologists, the documentation has to be in the form of photographs.

The use of all instruments requires training and competence but more skill is needed for indirect ophthalmoscopy and slit-lamp bio microscopy than for fundus photography. Newer, semi-automatic non mydriatic fundus cameras can be very easy to use. Media opacities will lead to image/ view degradation and all photographs/ images must be reviewed by trained personnel.

1. Follow-up Examination of Patients with Diabetic Retinopathy

In general, the follow-up history and examination should be similar to the initial examination. The assessment of visual symptoms, visual acuity, measurement of IOP and fundus examination are essential.

a. Follow-up History

- Visual symptoms
- Glycemic status (Haemoglobin A1c)
- Systemic status (e.g., pregnancy, blood pressure, serum lipid levels, renal status)

b. Follow-up Physical Exam

- Visual acuity
- Measurement of IOP
- Gonioscopy when indicated
- Slit-lamp bio microscopy
- Fundus examination

c. Ancillary Tests

- Fluorescein angiography is not needed to diagnose DR, proliferative DR or DME, all of which are diagnosed by means of the clinical exam.
- Fluorescein a ngiography can be used as a guide for treating DME and as a means of evaluating the cause(s) of unexplained decreased visual acuity. Fluorescein angiography can also identify macular

capillary non-perfusion or sources of capillary leakage resulting in DME as possible explanations for visual loss.

- OCT is the most sensitive method to identify sites and severity of DME.

d. Patient Education

- Discuss results of exam and implications.
- Encourage patients with DM but without DR to have annual screening eye exams.
- Inform patients that effective treatment for DR depends on timely intervention, despite good vision and no ocular symptoms.
- Educate patients about the importance of maintaining near-normal glucose levels, near-normal blood pressure and to control serum lipid levels.
- Communicate with the general physician (e.g. family physician, internist or endocrinologist) regarding eye findings.
- Provide patients whose conditions fail to respond to surgery and for whom treatment is unavailable with proper professional support (i.e. offer referrals for counseling, rehabilitative, or social services as appropriate).
- Refer patients with reduced visual function for vision rehabilitation and social services.

Table3: Follow-up Schedule and Management for Diabetic Retinopathy Severity in Indian context For all patients regardless of DR severity, optimize medical treatment for glycemic control, hypertension, and dyslipidemia.

Follow up Schedule	In Indian Settings
No apparent DR	Repeat examination annually
Mild non proliferative DR	Repeat examination annually
Moderate non proliferative DR	Repeat examination within 6-12 months
Severe non proliferative DR or proliferative DR	Pan-retinal photocoagulation
DME	Laser / Intra-vitreous injections of anti-VEGF agents / Steroids

IV. Treatment of Diabetic Retinopathy

Pan-retinal laser photocoagulation should be performed in patients with proliferative DR. There are benefits of early panretinal photocoagulation at the severe non proliferative DR stage for patients with type 2 diabetes. Other factors, such as poor compliance with follow up, impending cataract extraction or pregnancy and status of fellow eye will help in determining the timing of the panretinal photocoagulation.

1. Panretinal Photocoagulation (PRP)

a. Pretreatment Discussion with Patients

- Patients usually need numerous follow-up visits and may require supplementary laser treatment.
- PRP reduces the risk of visual loss and blindness.
- Although laser treatment is effective, some patients may still develop vitreous haemorrhage. The haemorrhage is caused by the diabetes and not by the laser; it may mean the patient needs more laser treatment.
- Laser treatment often reduces peripheral and night vision; treatment may moderately reduce central vision. This short-term side effect is compensated by the significant long-term reduction in severe vision loss and blindness in laser-treated patients.

b. Lenses for PRP

- The three-mirror Goldmann contact lens has a central opening for treating the posterior pole and side mirrors for treating the mid peripheral and peripheral retina. Disadvantages: small field of view, which requires continual manipulation of the lens to complete treatment. Spot size is set at 500µm.
- Newer wide-angle contact lenses are often used. Although the image is inverted, there is a large field of view allowing for many burns with the field while easily maintaining orientation to the disc and macula. The optics of these wide-angle lenses will affect the laser spot size on the retina (**Table 4**). Wide-angle indirect ophthalmoscopy lenses provide an inverted image, but show a large field of view and a magnification of the spot in the retina (Table 4). Scatter treatment can be applied to a large area of retina in a single image, and it is easy to visualize the disk and the macula.

Table 4: Laser Spot Size Adjustment Required for Different Lenses Contact

Lens	Field of Vision	Axial magnification	Spot magnification	Spot Size Setting for ~500 µm
Mainster Wide-Field	125°	0.46	1.50x	300µm
Volk TransEquator	120-125°	0.49	1.43x	300µm
Volk Quad/Aspheric	130-135°	0.27	1.92x	200 to 300µm
Mainster PRP 165	160°	0.27	1.96x	200 to 300 µm

c. Technique for PRP

- The pupil should be fully dilated and topical anaesthesia is used. Retrobulbar or subtenons anaesthesia to reduce pain and decrease eye motion can be employed as necessary.
- The most common wavelengths used are Argon green, blue green (generally avoided currently) and 532 green laser, using the slit-lamp delivery system. In case of hazy media, Krypton red or diode red laser (814 nm) can be used. Slit-lamp treatment is most commonly done through a contact lens but can also be performed using indirect ophthalmoscopy. For example, when treatment is given under general anaesthetic.
- Typical initial settings on the Argon laser would be 500 µm spot size, a 0.1 second exposure and 250-270 mw power. The power is gradually increased until a whitish reaction is obtained on the retina. The lesions are placed 1 burn width apart. (**Table 5**)
- A total of 1600-3000 burns are placed in 1 or more sittings, carefully avoiding the macular area and any areas of tractional elevation of the retina. The burns are placed 2 to 3 disc diameters away from the centre of the macula and 1 disc diameter away from the disc, usually outside the arcades and extended peripherally up to the equator and beyond.
- Laser treatment should not be applied over major retinal veins, pre retinal haemorrhages, darkly pigmented chorio retinal scars, or within 1 DD (200-300 µm) of centre of macula, so as to avoid risk of haemorrhage or large scotomas.
- Other considerations:
 - Additional photocoagulation is needed if there is evidence of worsening of proliferative DR.
 - Add laser burns in between scars of initial treatment further peripherally and also at the posterior pole, sparing the area within 500-1500 µm from the centre of the macula.
 - Favour quadrants with active new vessels or areas with intra retinal micro vascular abnormalities where scars are more widely spaced and areas of severe ischemia not previously treated, such as the temporal part of the posterior pole.
 - Direct treatment of NVE in between scars is possible.

For non-commercial use

- A subthreshold micropulse diode laser or multi-spot laser can be used.

d. Panretinal (Scatter) Photocoagulation Technique Following Diabetic Retinopathy Clinical Research Network (DRCRNet) Consensus

Panretinal (scatter) photocoagulation initially consists of 1200 to 1600 burns (or the equivalent area treated with a multi-spot laser), with a spot size on the retina of approximately 500 µm given over 1 to 3 sittings and completed within eight weeks (56) days of initiation. **(Table 5)**

Table 5: The burn characteristics for panretinal photocoagulation:

Size (on retina):	500 µm
Exposure:	0.1 seconds recommended, 0.05 to 0.2 allowed
Intensity:	mild white (i.e. 2+ to 3+ burns)
Distribution:	edges 1 burn width apart
Number of sessions/sittings:	1 to 3
Nasal proximity to disk:	No closer than 500 µm
Temporal proximity to centre:	No closer than 3000 µm
Superior/inferior limit:	No further posterior than 1 burn within the temporal arcades
Extent:	Arcades (~3000 µm from the macular centre) to at least the equator
Total number of burns:	1200 – 1600 There may be instances where 1200 burns are not possible such as the development of vitreous haemorrhage or inability to complete a sitting precluding completion of the PRP session. Similarly, there may be clinical situations in which more than 1600 burns are needed such as initial difficulty with laser uptake due to media opacity.
Wavelength:	Green or yellow (red can be used if vitreous haemorrhage is present)

2. Treatment For Diabetic Macular Edema

a. Indian Settings

- Optimize medical treatment: Improve glycemic control if HbA1c > 7.5% as well as associated systemic hypertension or dyslipidemia.
- Mild or moderate DME without centre involvement (e.g., circinate HE ring threatening the centre of the macula or when no vision loss has occurred in spite of centre involvement): Consider focal laser to leaking micro aneurysms. No treatment is applied to lesions closer than 300 µm from the centre of the macula.
- Severe DME with centre involvement and associated vision loss*: intra-vitreous anti- VEGF treatment (e.g., with ranibizumab [Lucentis] 0.3 or 0.5mg, bevacizumab [Avastin] 1.25mg, or Aflibercept [Eylea] 2mg therapy). Consideration should be given to monthly injections followed by treatment interruption and re-initiation based on visual stability and OCT. Patients should be monitored almost monthly with OCT to consider the need for treatment. Persistent retinal thickening and leaking points: consider laser treatment after 24 weeks. Treatment with intra-vitreous triamcinolone may be considered, especially in pseudophakic eyes. (Annex Figures 3 and 4). Injections are to be given with all sterile precautions (Annexure).
- DME associated with proliferative DR: combined intra-vitreous anti-VEGF therapy and PRP should be considered.
- Vitreomacular traction or epiretinal membrane on OCT: pars plana vitrectomy may be indicated.

b. Laser Technique for Macular Oedema

- i. Focal macular treatment includes focal laser treatment of micro aneurysms and grid treatment of areas of diffuse leakage and focal non-perfusion within 2DD of centre of the macula. **(Table 6)**
- ii. Laser parameters used are 50-100 µm spot size, 120-150 mW energy and very light gray intensity of the burn. Care is taken to demarcate and avoid the foveal avascular zone.
- iii. If DME is associated with large areas of macular ischemia, only the areas of retinal thickening are treated.

Table 6: Modified-ETDRS and the Mild Macular Grid Laser Photocoagulation Techniques

Burn Characteristic	Direct/Grid Photocoagulation (Modified-ETDRS technique)	Mild Macular Grid Photocoagulation Technique
Direct treatment	Directly treat all leaking micro aneurysms in areas of retinal thickening between 500 and 3000 µm from the centre of the macula (but not within 500 µm of disc)	Not applicable
Change in MA colour with direct treatment	Not required, but at least a mild gray-white burn should be evident beneath all micro aneurysms	Not applicable
Burn size for direct treatment	50-100 µm	Not applicable
Burn duration for direct treatment	0.05 to 0.1 sec	Not applicable
Grid treatment	Applied to all areas with diffuse leakage or nonperfusion within area described below for treatment	Applied to entire area described below for treatment (including unthickened retina)
Area considered for grid treatment	<ul style="list-style-type: none"> • 500 to 3000 µm superiorly, nasally and inferiorly from centre of macula • 500 to 3500 µm temporally from macular centre • No burns are placed within 500 µm of disc 	<ul style="list-style-type: none"> • 500 to 3000 µm superiorly, nasally and inferiorly from centre of macula • 500 to 3500 µm temporally from macular centre • No burns are placed within 500 µm of the disc
Burn size for grid treatment	50-100 µm	50 µm
Burn duration for grid treatment	0.05 to 0.1 sec	0.05 to 0.1 sec
Burn intensity for grid treatment	Barely visible (light gray)	Barely visible (light gray)
Burn Separation for Grid Treatment	Two visible burn widths apart	200 to 300 total burns evenly distributed over the treatment area outlined above (approx. two to three burn widths apart)
Wavelength (grid and focal Treatment)	Green to yellow wavelengths	Green

3. Indications for Vitrectomy

- Severe vitreous haemorrhage of 1–3 months duration and that does not clear spontaneously.
- Advanced active proliferative DR that persists despite extensive PRP.
- Traction macular detachment of recent onset.
- Combined traction-rhegmatogenous retinal detachment.
- Tractional macular oedema or epiretinal membrane involving the macula.

Annexes

VISION 2020: RIGHT TO SIGHT-INDIA GUIDELINES FOR DIABETIC RETINOPATHY

Annexure 1: Tables

Table 1: Features of Diabetic Retinopathy (also see the photographs continued in the annex)

Feature	Description	Assessment Considerations
Micro aneurysms	Isolated, spherical, red dots of varying size. They may reflect an abortive attempt to form a new vessel or may simply be a weakness of capillary vessel wall through loss of normal structural integrity.	They are easiest seen on fluorescein angiography
Dot haemorrhages	Dot haemorrhages cannot always be differentiated from micro aneurysms as they are similar in appearance but with varying size.	The term dot haemorrhage/ Micro aneurysm (H/Ma) is often used.
Blot haemorrhages	Formed where clusters of capillaries occlude leading to formation of intra retinal blot haemorrhages.	The lesion can be seen to be in the outer plexiform layer on fluorescein angiography where it does not mask the overlying capillary bed unlike dot and flame haemorrhages, which lie more superficially in the retina.
Cotton wool spots Intra retinal micro vascular anomalies	These represent the swollen ends of interrupted axons where build-up of axoplasmic flow occurs at the edge of the infarct. These are dilated capillary remnants following extensive closure of capillary network between arteriole and venule. Associated features include: <ul style="list-style-type: none"> venous beading (foci of venous endothelial cell proliferation that have failed to develop into new vessels), Venous reduplication (rare), Venous loops (thought to develop due to small vessel occlusion and opening of alternative circulation) and Retinal pallor and white vessels 	These features are not exclusive to DR and do not in themselves appear to increase the risk of new vessel formation. For example, they may occur in hypertension HIV/AIDS. They are easiest seen on fluorescein angiography.
Macular changes In non-proliferative retinopathy – Macular oedema	Thickening of retina takes place due to accumulation of exudative fluid from damaged outer blood-retina barrier (extracellular oedema) or	The appearance of macular oedema can be appreciated on stereoscopic examination or inferred by the

For non-commercial use

- Macrovascular disease	as a result of hypoxia, leading to fluid accumulating within individual retinal cells (intracellular oedema). It may be focal or diffuse. Flame haemorrhage and cotton wool spot formation. May occur due to arteriolar occlusion, without capillary occlusion, which frequently affects the horizontal nerve fiber layer of the retina.	presence of intra retinal exudate.
Optic disc changes	Occasionally swollen optic discs may be seen (diabetic papillopathy) in diabetic patients.	In diabetic papillopathy, vision is usually not significantly impaired.

Table 2: Features of Proliferative Diabetic Retinopathy

Feature	Description	Assessment Considerations
New vessels at the disc (NVD)	New vessels at the discs usually arise from the venous circulation on the disc or within 1 disc diameter of the disc NVD.	In order to differentiate NVD from fine normal small blood vessels note that the latter always taper to an end and do not loop back to the disc, while NVD always loop back, may form a chaotic net within the loop, and have the top of the loop of wider diameter than the base.
New vessels elsewhere (NVE)	New vessels, which usually occur along the border between healthy retina and areas of capillary occlusion.	Not to be confused with intra retinal micro vascular abnormalities, which occur within areas of capillary occlusion.
Other sites of new vessels	New vessel formation on the iris (NVI) is uncommon but represents potentially more advanced ischemic changes. New vessel formation on the anterior hyaloid surface occurs rarely postvitrectomy if insufficient laser has been applied to the peripheral retina.	It is useful to perform gonioscopy in such cases to exclude new vessels in the anterior chamber angle (NVA), which can lead to neovascular glaucoma.
Fibrous proliferation	In proliferative retinopathy, new vessels grow on a platform of glial cells.	

Adapted from British The Royal College of Ophthalmologists Diabetic Retinopathy Guidelines December 2012.

Table 3: Available Assessment Instruments and Their Advantages and Disadvantages

Technique	Advantages	Disadvantages	Recommendation
Direct ophthalmoscopy [#]	<ul style="list-style-type: none"> • Mobile • Inexpensive 	<ul style="list-style-type: none"> • Requires pupil dilation • Small field • Low sensitivity: even with a trained practitioner and red free illumination, small micro vascular abnormalities may be difficult to detect • Less effective than slit-lamp bio microscopy through dilated pupils • No ability to retrospectively audit 	<ul style="list-style-type: none"> • Optional for screening • Pupils must be dilated

Indirect ophthalmoscopy [#]	<ul style="list-style-type: none"> • Mobile • Large field • Relatively inexpensive 	<ul style="list-style-type: none"> • Requires pupil dilation • Even with a trained practitioner and red free illumination, small microvascular abnormalities may be difficult to detect • Less effective than slit-lamp bio microscopy through dilated pupils • No ability to retrospectively audit 	<ul style="list-style-type: none"> • Optional for screening • Pupils must be dilated
Slit-lamp bio microscopy	<ul style="list-style-type: none"> • Large field 	<ul style="list-style-type: none"> • Requires pupil dilation • Immobile • Requires special lenses • No ability to retrospectively audit 	Required for ophthalmic examination
Non mydriatic retinal photography	<ul style="list-style-type: none"> • Large field • Can be used by non-medically trained staff • No dilation required in 80-90% of cases • Some are portable - can be transported to the community in mobile units • Can be linked to computers and images can be stored for the long term • Allows objective comparison of the same person, or between different groups of people, examined at different times or by different professionals • Can be used as a patient education tool, giving immediacy and personal relevance • Readily recalled for evaluation of screener performance and audit of grading 	<ul style="list-style-type: none"> • Relatively expensive • A dark space is required for maximum pupil dilation • Auditable 	<ul style="list-style-type: none"> • Recommended for screening
Non mydriatic retinal photography used with mydriasis	<ul style="list-style-type: none"> • As above except pupils are dilated for better quality photos 	<ul style="list-style-type: none"> • As above • Requires pupil dilation 	<ul style="list-style-type: none"> • Optional
Mydriatic retinal photography (conventional fundus camera)	<ul style="list-style-type: none"> • Large field 	<ul style="list-style-type: none"> • Requires pupil dilation • Expensive • Bright flash constricts the pupil for a long time 	<ul style="list-style-type: none"> • Optional • Desirable in ophthalmic centre

For non-commercial use

Fluorescein angiography	<ul style="list-style-type: none"> • Only method of assessing capillary circulation 	<ul style="list-style-type: none"> • Invasive and needs general health status assessment • Expensive • Dilatation needed • Cannot be used by non-medically trained staff 	<ul style="list-style-type: none"> • Desirable in ophthalmic centre
OCT	<ul style="list-style-type: none"> • One of the best ways to assess macular oedema (retinal thickening and Intra-retinal oedema) 	<ul style="list-style-type: none"> • Expensive • Dilatation needed • Cannot be used by non-medically trained staff 	<ul style="list-style-type: none"> • Desirable in ophthalmic centre
Fundus autofluorescence	<ul style="list-style-type: none"> • A form of functional imaging, giving insights into the metabolic activity of the retinal pigment epithelium. 	<ul style="list-style-type: none"> • Role not clearly understood 	<ul style="list-style-type: none"> • Optional high-resource settings

Equipment

Core/essential: for screening, initial assessment, and follow up:

- Non-mydratic retinal (fundus) photography (recommended for screening).
- Indirect ophthalmoscopy (optional for screening, panoramic view, low magnification). Pupils must be dilated.
- Noncontact biconvex indirect lenses used with the slit lamp (90 D for screening, 78 D for more magnification).
- Direct ophthalmoscopy (optional for screening). Pupils must be dilated.
- Three-mirror contact lens used with slit lamp for stereoscopic and high-resolution images of the macula (evaluation of macular oedema). Pupils must be dilated.
- Slit-lamp biomicroscope.
- Laser equipment: Currently, the most used lasers are (1) The green laser 532 nm, frequency-doubled Nd:YAG or 514 nm argon laser. The 810 nm infrared laser, or diode laser – this causes deeper burns with a higher rate of patient discomfort, but tend to be cheaper, is effective, and requires less maintenance.

Desirable in reference centers:

- OCT
- Fluorescein angiography
- Mydratic retinal photography (large field conventional fundus camera)
- Green lasers are the most used, but the pattern-laser method, with a predetermined multi-spot treatment cascade and the 577 nm yellow laser can be used in selected cases

IAPB Standard List of Equipment:

The online version of the International Agency for the Prevention of Blindness (IAPB) Standard List provides information for eye health providers on a carefully evaluated range of eye care technologies, supplies, and training resources suitable for use in settings with limited resources.

For more information and to get access, please register and log on at IAPB.standardlist.org.

Only registered users have access to the IAPB Standard List catalogue. Please be aware the registration process may take a few days for approvals to be granted.

Annexure 2: Suggested Indicators for Evaluation of DR Programs

- a. Prevalence of diabetic retinopathy related blindness and visual impairment*
- b. Proportion of blindness and visual impairment due to DR*
- c. Last eye examination for DR among known persons with diabetes (males/females)*
 - Never had eye examination for DR
 - 0–12 months ago
 - 13–24 months ago
 - >24 months ago
 - Could be simplified as: never/0-12 months ago/>12 months ago
- d. Number of patients who were examined for DR during last year
- e. Number of patients who received laser and/or anti-VEGF treatment during last year

This absolute number could be used to define ratios such as:

- f. Number of patients who received laser and/or anti-VEGF treatments per million general population per year [equivalent to Cataract Surgical Rate (CSR)]
- g. Number of patients who received laser and/or anti-VEGF treatments per number of patients with diabetes in a given area (hospital catchment area, health district, region, country)
 - Numerator: number of laser and/or anti-VEGF treatments during the last year
 - Denominator: number of patients with diabetes (population x prevalence of DM; source: IDF Atlas)
- h. Number of patients who received laser and/or anti-VEGF treatments per number of persons with vision-threatening DR in a given area (hospital catchment area, health district, region, country)
 - Numerator: number of laser and/or anti-VEGF treatments during the last year
 - Denominator: number of patients with vision-threatening DR (population x prevalence of DM x 0.117; source: IDF Atlas)

* Data available from RAAB surveys

0.117: Estimated average prevalence of vision-threatening DR.

Yau JW, Rogers SL, Kawasaki R, et al. Global Prevalence and Major Risk Factors of Diabetic Retinopathy. *Diabetes Care*. Mar 2012; 35(3):556-564.

Annexure 3: Flowcharts

Figure 1: Screening for Diabetic Retinopathy

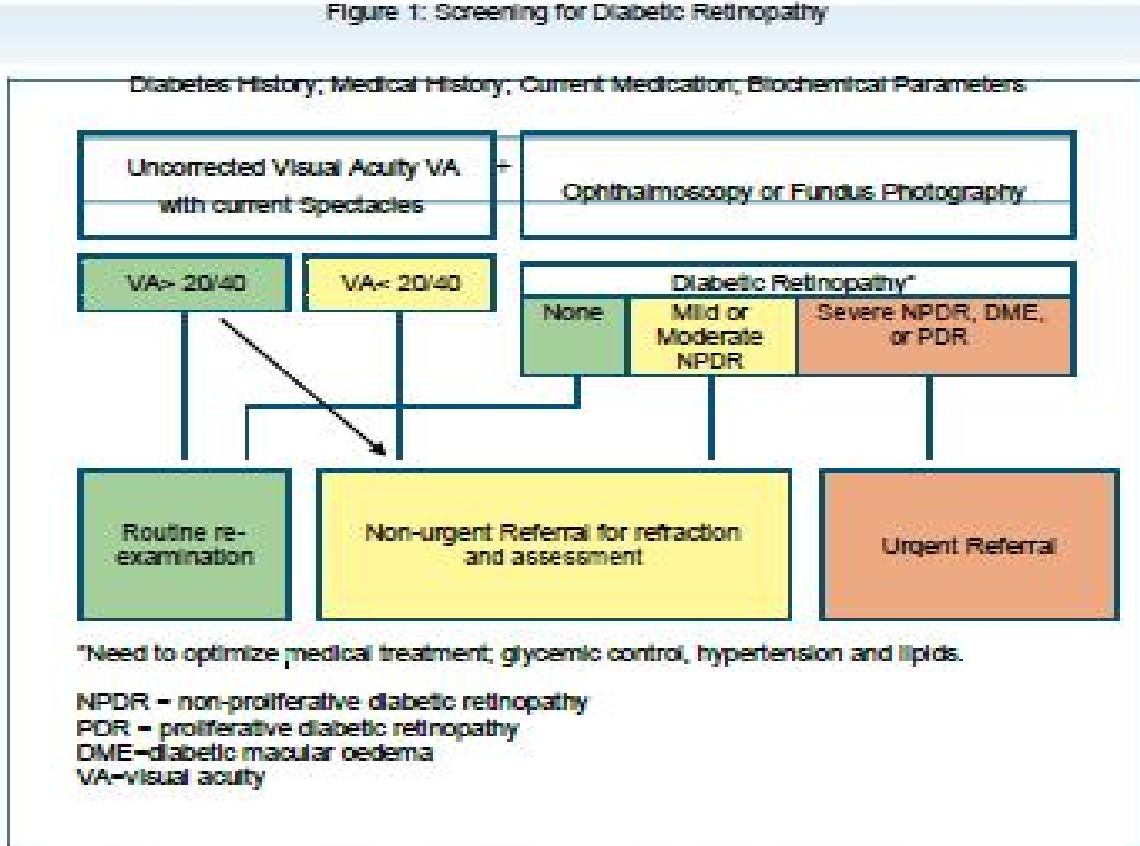
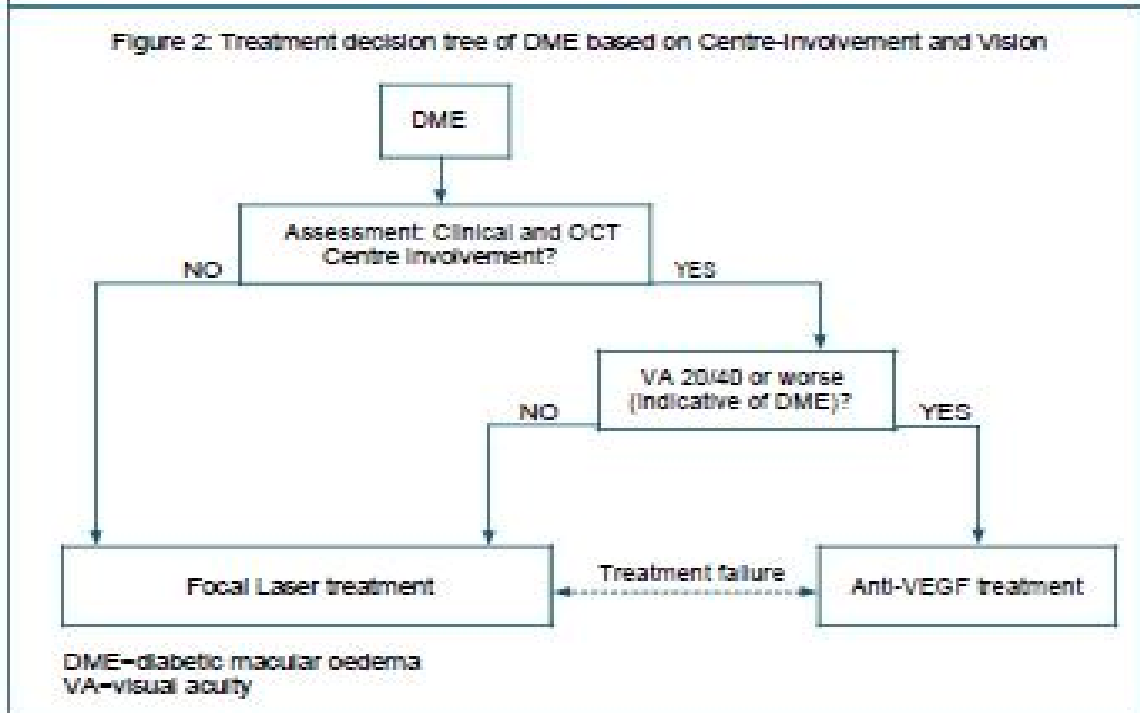
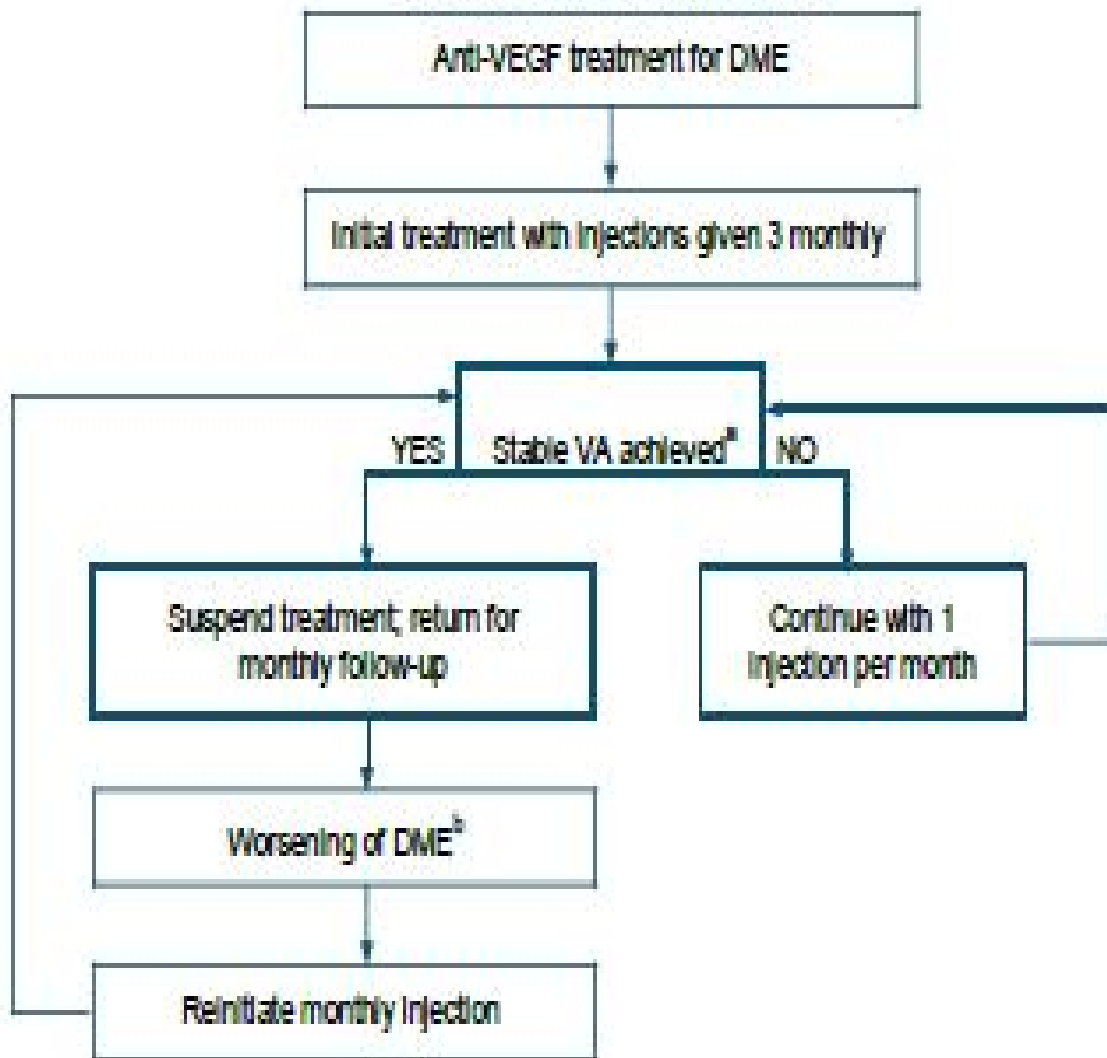


Figure 2: Treatment decision tree of DME based on Centre Involvement and Vision



For non-commercial use

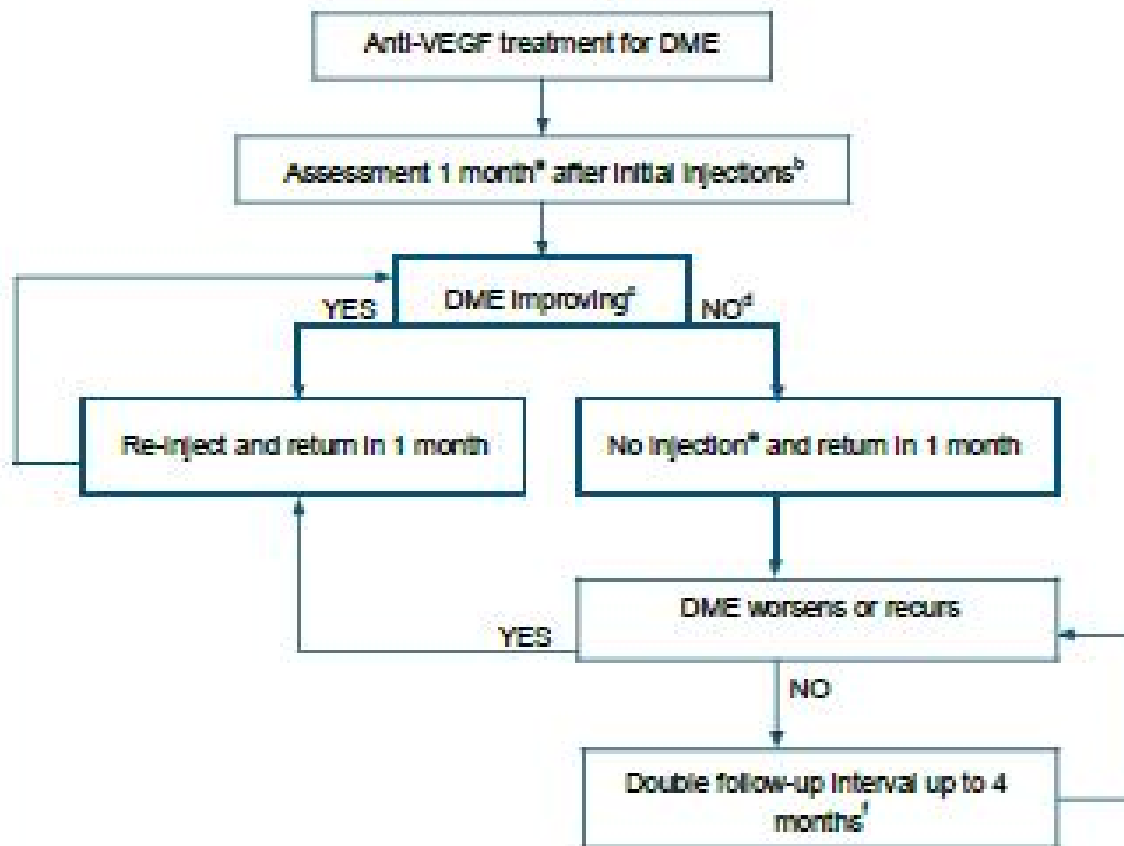
Figure 3: Anti-VEGF treatment decision tree based on the RESTORE study treatment and re-treatment schedule



- a. VA was considered to have stabilised if there was no (further) improvement in best corrected visual acuity (BCVA) at the last 2 consecutive visits, or if a BCVA letter score of 6/6 was observed at the last 2 consecutive visits.
- b. Decrease in BCVA and confirmed by OCT and/or other anatomical and clinical assessments.

VEGF=vascular endothelial growth factor
 DME=diabetic macular oedema
 VA=visual acuity

Figure 4: Anti-VEGF treatment decision tree based on the DRCR.net re-treatment and follow-up schedule



- In the DRCR.net study, 4-week, not 1-month, intervals were used.
- The DRCR.net study required 4 injections of intravitreal ranibizumab every 4 weeks initially; it is not known whether a different number of injections initially would have worked as well. DRCR.net also required 2 additional injections at months 5 and 6 if oedema persisted and success had not been met, even in the absence of improvement.
- Relevant details from the DRCR.net study: 1) DRCR.net "Improvement" on Zeiss Stratus OCT >10% decrease in central subfield thickness; 2) Even if no longer improving on OCT, injections continued if VA "improvement" (unless 6/6 or better); 3) VA improvement defined as 5 or more letter increase on Electronic ETDRS Visual Acuity Test.
- In the DRCR.net study, if focal/grid laser was deferred at baseline, it was added at or after 24 weeks if oedema still present and OCT central subfield and vision no longer improving.
- In the DRCR.net study, all patients received at least 4 injections 4 weeks apart. The decision to re-inject was at investigator discretion, starting at 16 weeks for "success", defined as VA better than 6/6 or OCT central subfield <250 µm. Starting at 24 weeks, re-injection was also at investigator discretion if no improvement in OCT central subfield or vision.
- The DRCR.net study continued follow-up every 4 weeks through the 52-week visit and did not permit extension of follow-up until after the 52-week visit. If injection was withheld due to no improvement or success at 3 consecutive visits following the week 52 visit, follow-up interval was doubled to 8 weeks and then again to 16 weeks if still no change.

VEGF=vascular endothelial growth factor
 DME=diabetic macular oedema
 VA=visual acuity

For non-commercial use

Annexure 4: Intra-vitreous technique for Anti-VEGF or steroids

Location of the Procedure – A sterile Operation theatre-based procedure is strongly recommended.

Pre-operative Assessment – A thorough pre-injection check of the eye and ocular adnexa to rule out ocular infections is mandatory. High risk patients, especially, those receiving Intravitreal Bevacizumab (Avastin), preferably, ought to be assessed by a physician for fitness for the procedure.

Surgeons and Staff – The personnel involved in the procedure need to follow the sterile precautions as mandated for a regular surgical procedure. This involves the conventional wearing of sterile surgical gowns and the use of sterile surgical gloves, cap and masks for the procedure. The patient's identity, case record and adequate pupillary dilation is verified prior to the procedure.

Local Asepsis & Anaesthesia– The patients need to be draped using a standard surgical drape after the conventional betadine cleansing of the external lids. 2-3 drops of 5% Povidone-Iodine Solution (Betadine) may be instilled into the conjunctival sac and flushed with saline after 30 seconds. Local anaesthesia may be achieved using 4% Lignocaine drops. Alternatively, a cotton pledget/swab soaked in 4% lignocaine may be dabbed onto the site of injection.

The Injection procedure – A sterile syringe containing the drug mounted with a 30 Gauge needle is used. The preferred site of injection is the inferotemporal quadrant (4mm from the limbus for phakic patients; 3.5mm for pseudophakic patients; 3mm for aphakic patients). The drug is injected into the midvitreous cavity after visualizing the needle tip. The injection site is tamponaded with a sterile cotton pledget to reduce reflux. Indirect ophthalmoscopy may be done to assess for central retinal artery pulsations (which would necessitate an anterior chamber paracentesis to relieve the same), to confirm drug delivery and check the site of injection.

Postoperatively, topical antibiotics may be prescribed for 5 days.

Bilateral simultaneous Intra-vitreous injections are to be avoided barring exceptional cases such as pediatric patients or mentally challenged patients requiring general anaesthesia for the procedure.

The standard doses for the conventional pharmacotherapies are:

- Ranibizumab (Lucentis) – 0.5mg/0.05 ml
- Bevacizumab (Avastin) – 1.25mg/0.05ml
- Triamcinolone – 4mg/0.1ml or 2mg/0.05ml.

Annexure 5: Photographs

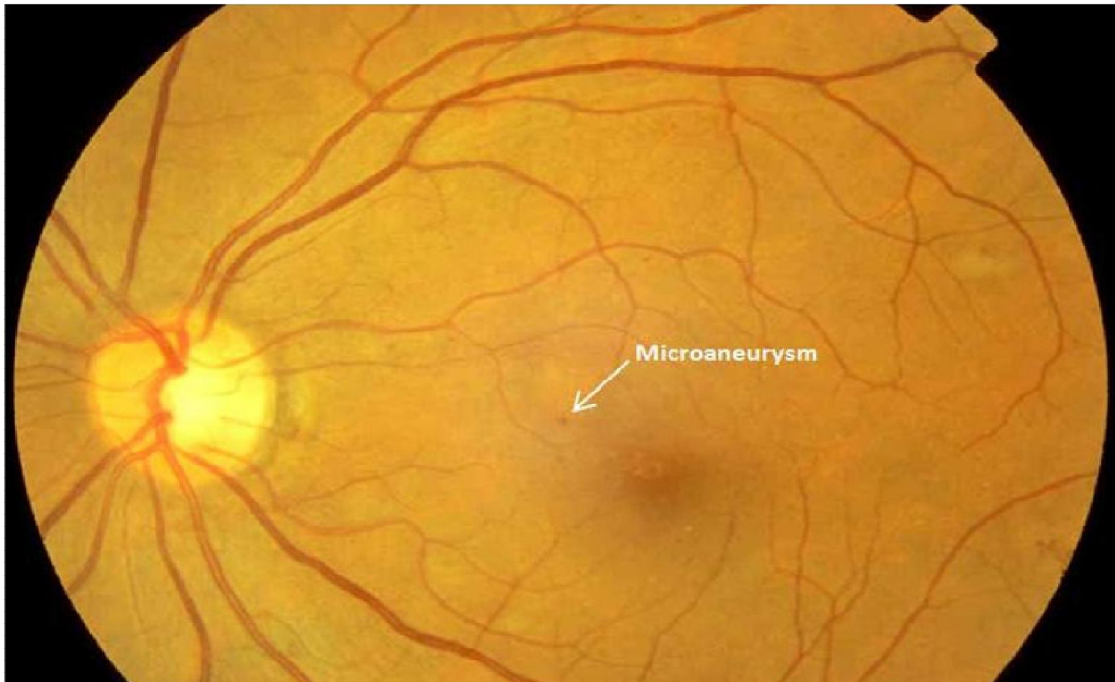


Figure 1: Mild non-proliferative diabetic retinopathy with micro aneurysms

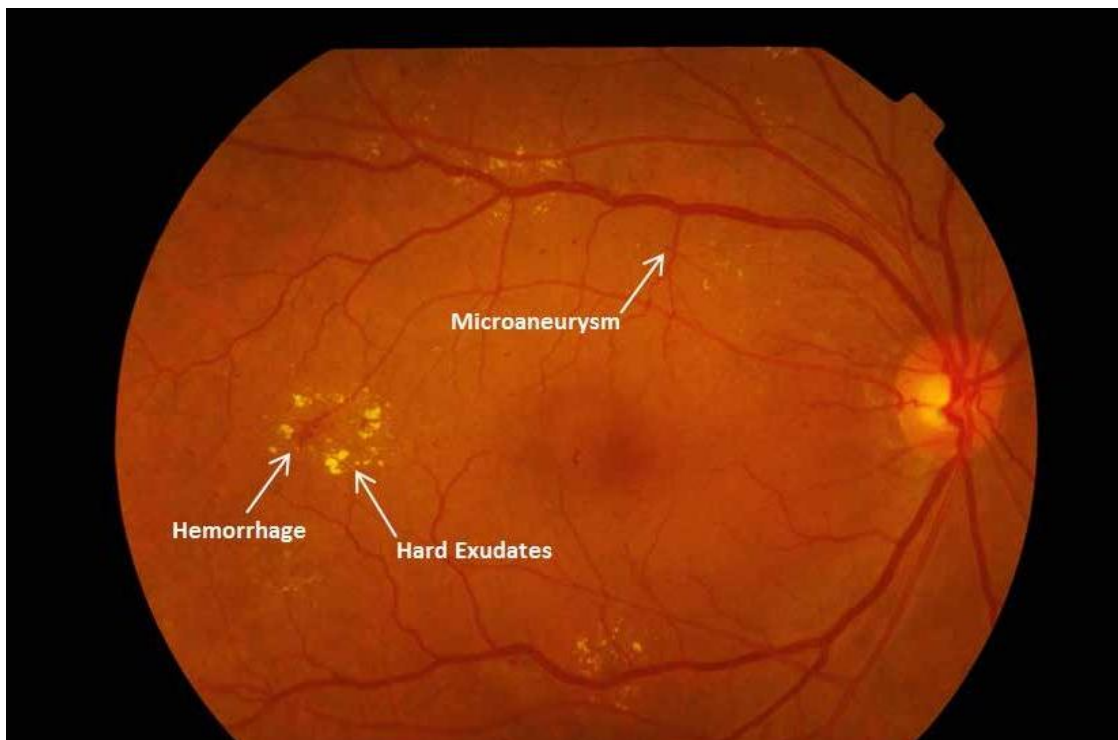


Figure 2: Moderate non-proliferative diabetic retinopathy with haemorrhages, hard exudates and micro aneurysms

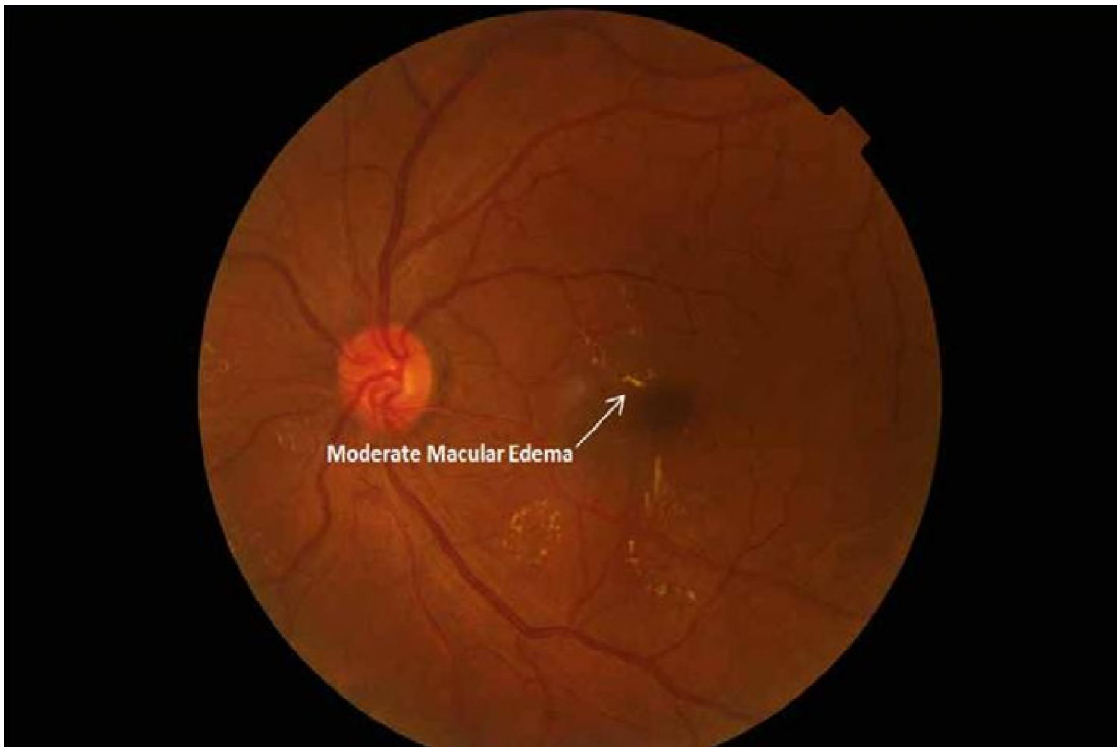


Figure 3: Moderate non-proliferative diabetic retinopathy with moderate macular oedema, with hard exudates approaching the centre of the macular.

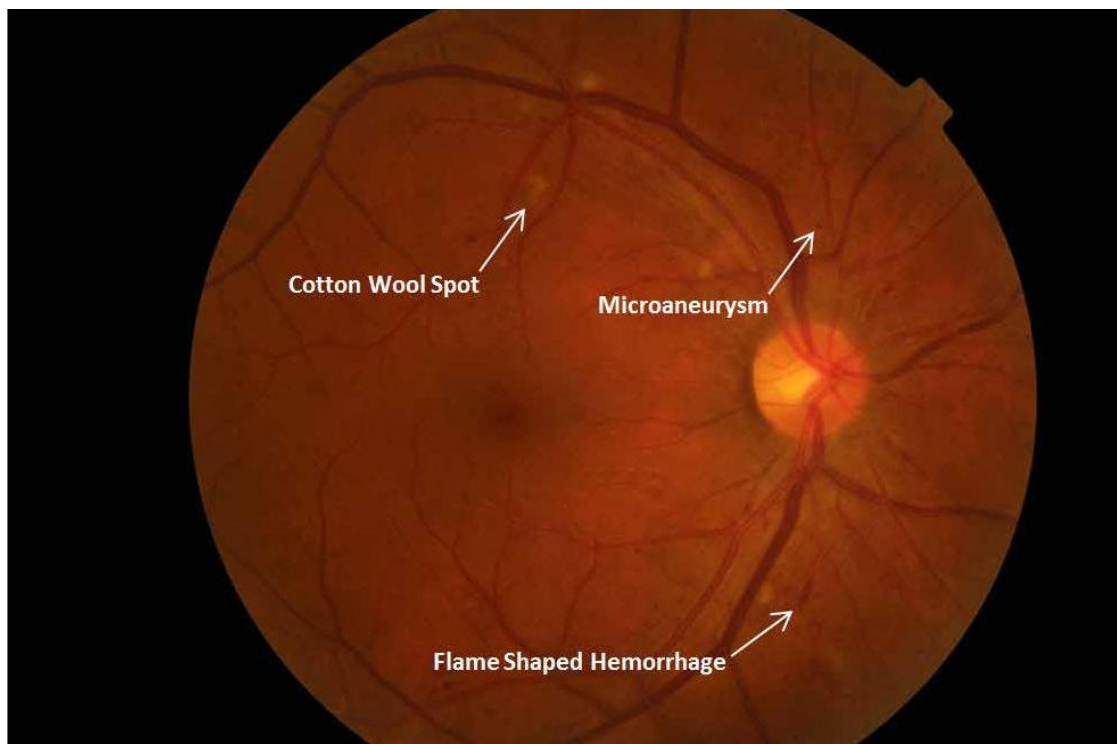


Figure 4: Moderate non-proliferative diabetic retinopathy with no diabetic macular oedema

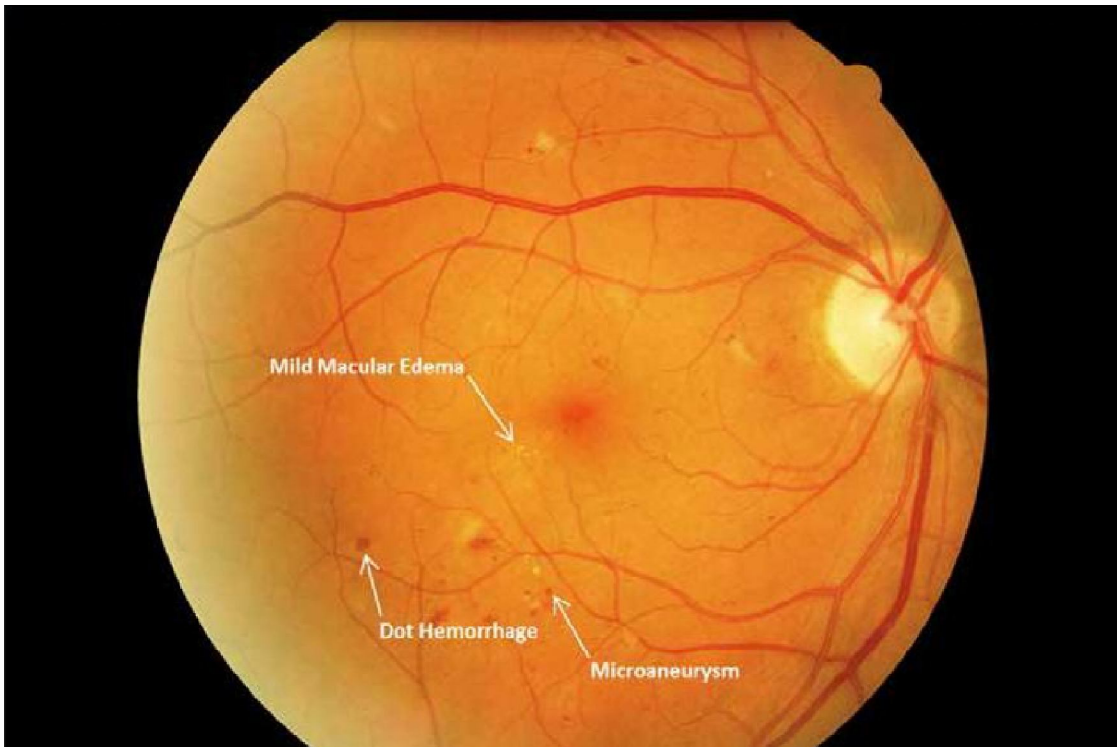


Figure 5: Moderate non-proliferative diabetic retinopathy with mild diabetic macular oedema

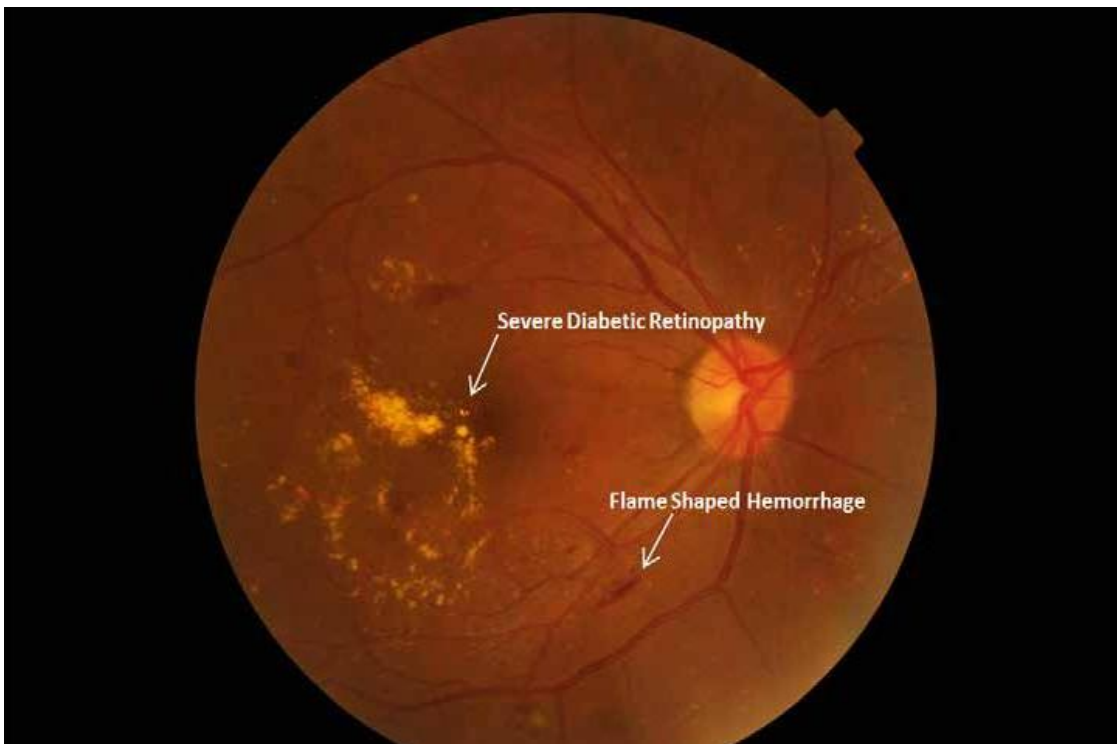


Figure 6: Moderate non-proliferative diabetic retinopathy with severe macular oedema

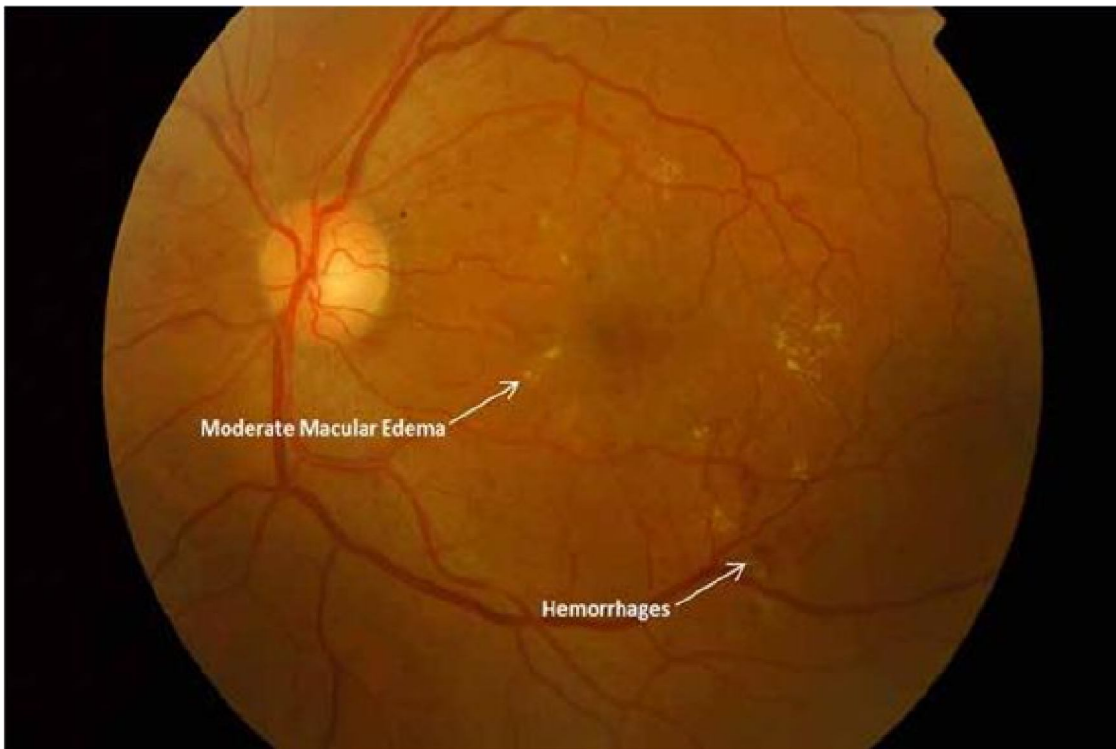


Figure 7a: Moderate non-proliferative diabetic retinopathy with moderate macular oedema

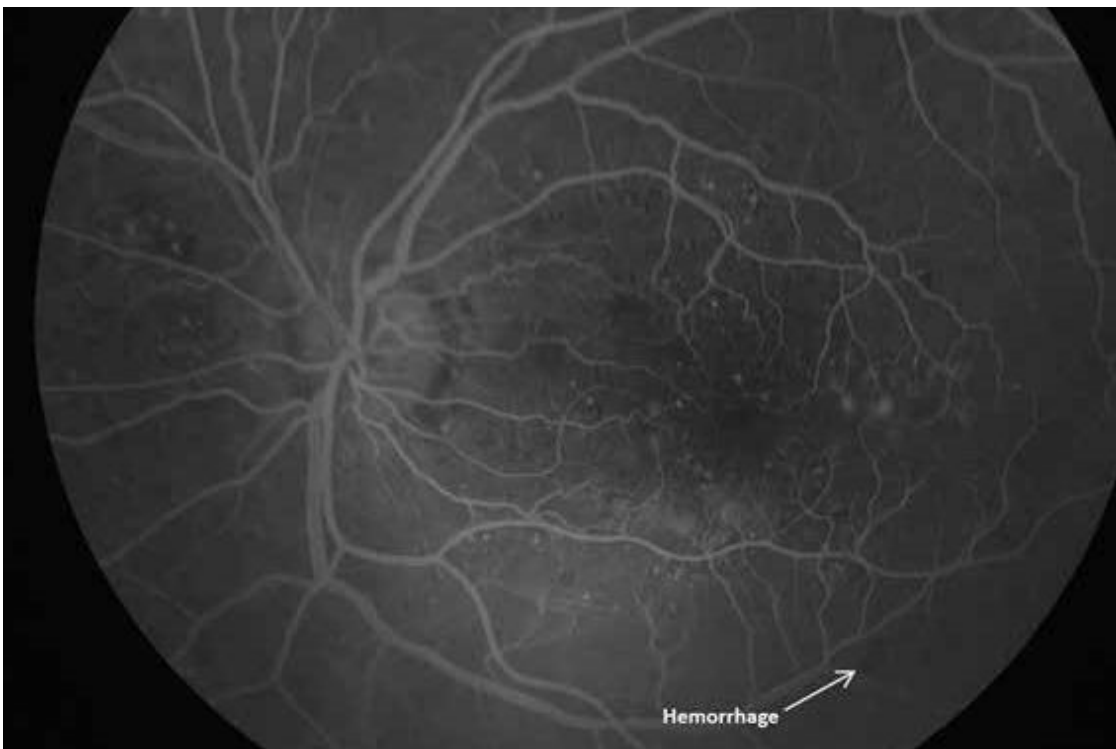

Figure 7b: Fundus Fluorescein Angiogram showing moderate non-proliferative diabetic retinopathy with moderate macular oedema

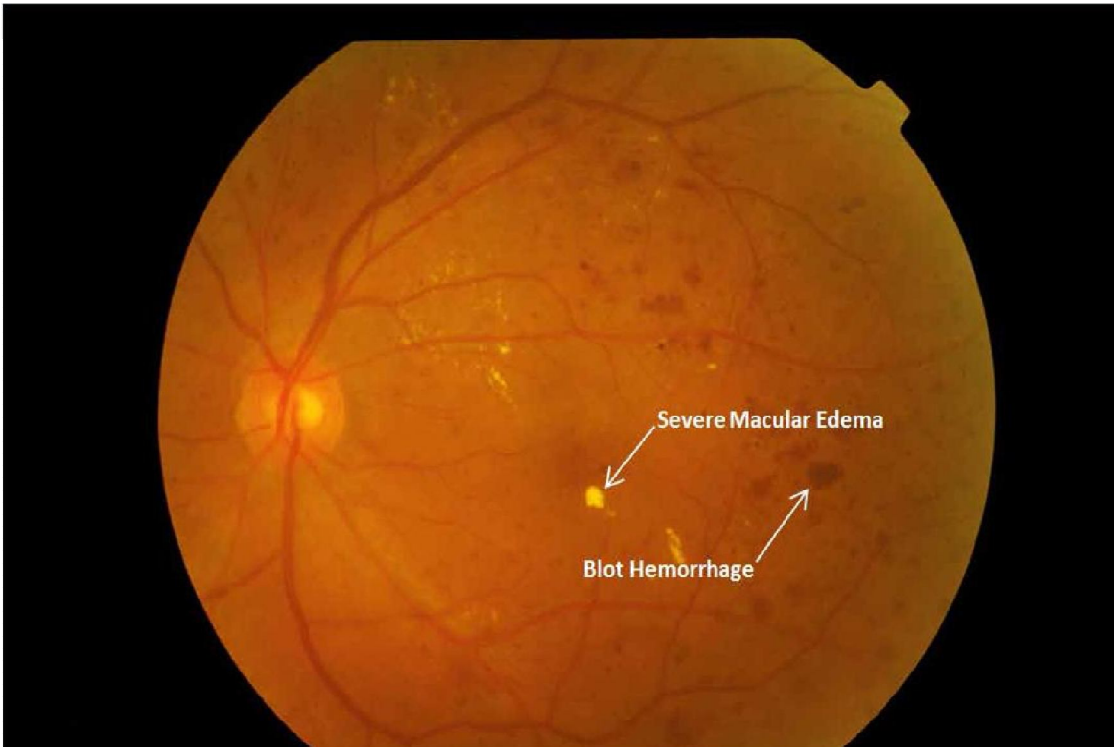


Figure 8: Severe non-proliferative diabetic retinopathy with severe diabetic macular oedema

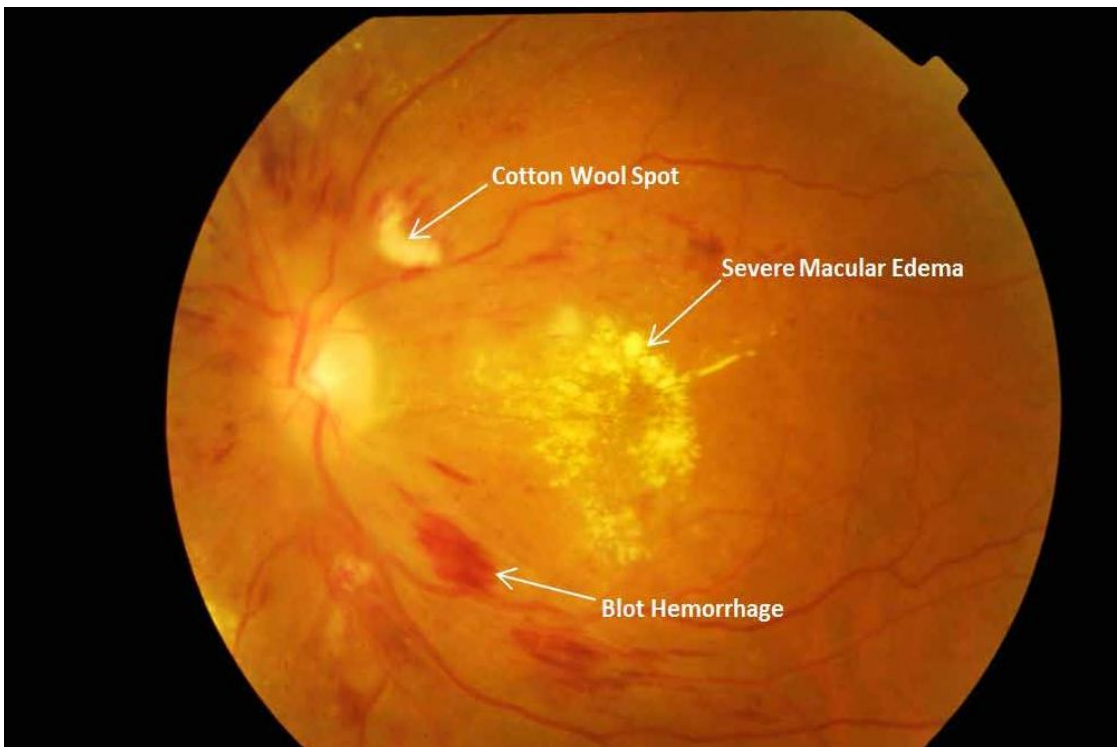


Figure 9: Severe non-proliferative diabetic retinopathy with severe diabetic macular oedema

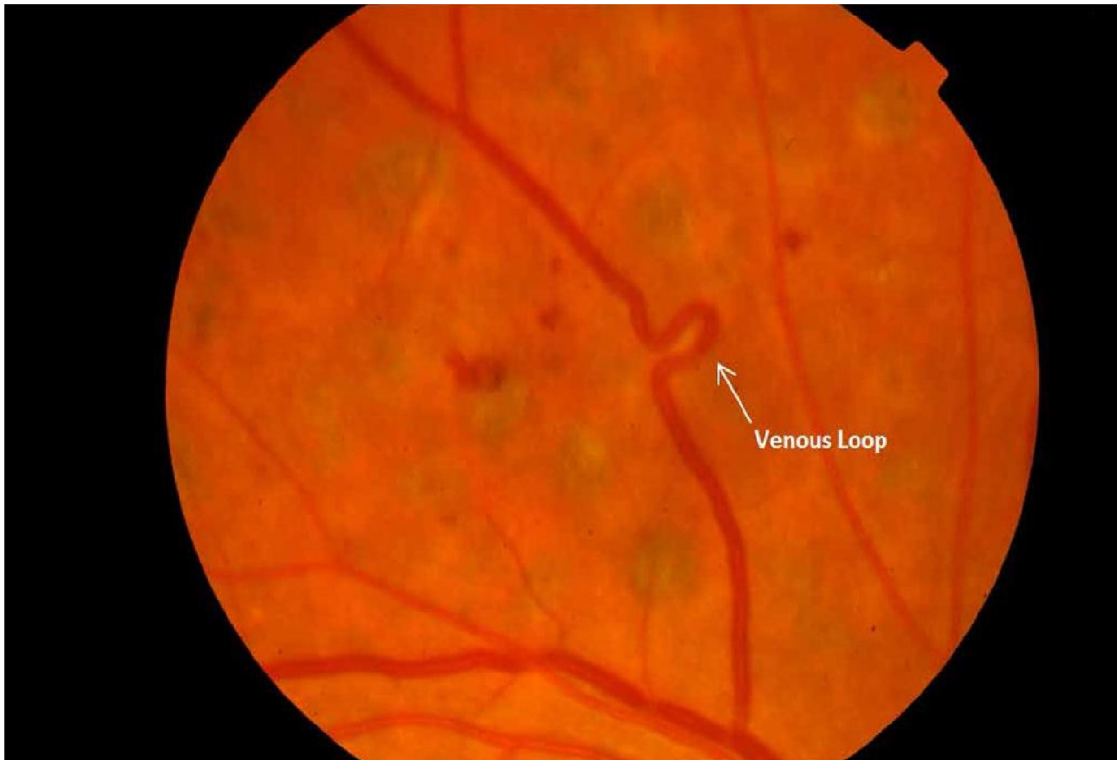

Figure 10: Severe non-proliferative diabetic retinopathy with venous loop

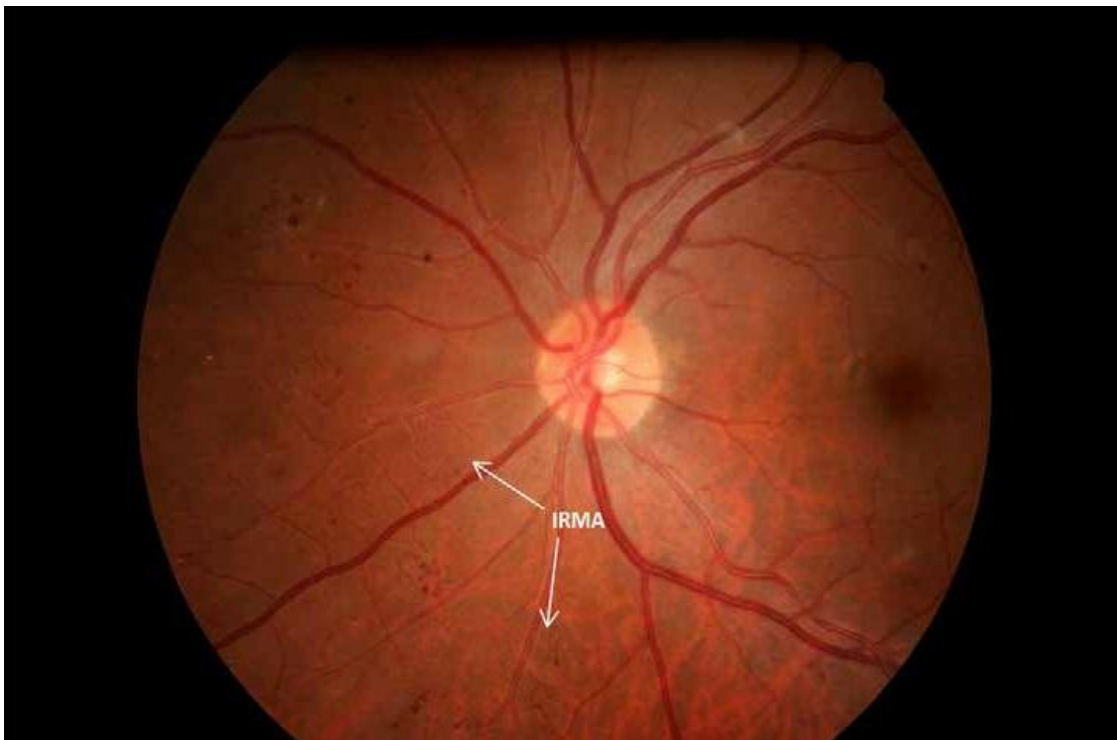


Figure 11: Severe non-proliferative diabetic retinopathy with intra-retinal micro vascular abnormality (IRMA)

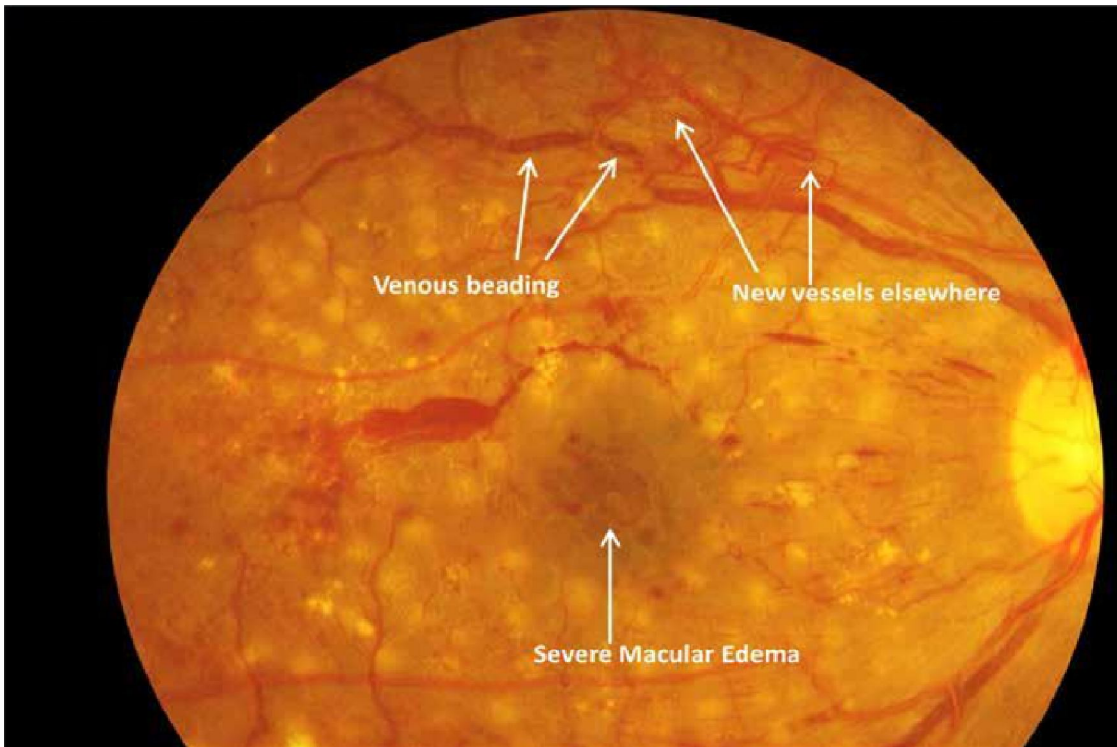


Figure 12: Proliferative diabetic retinopathy with venous beading, new vessels elsewhere (NVE) and severe diabetic macular oedema

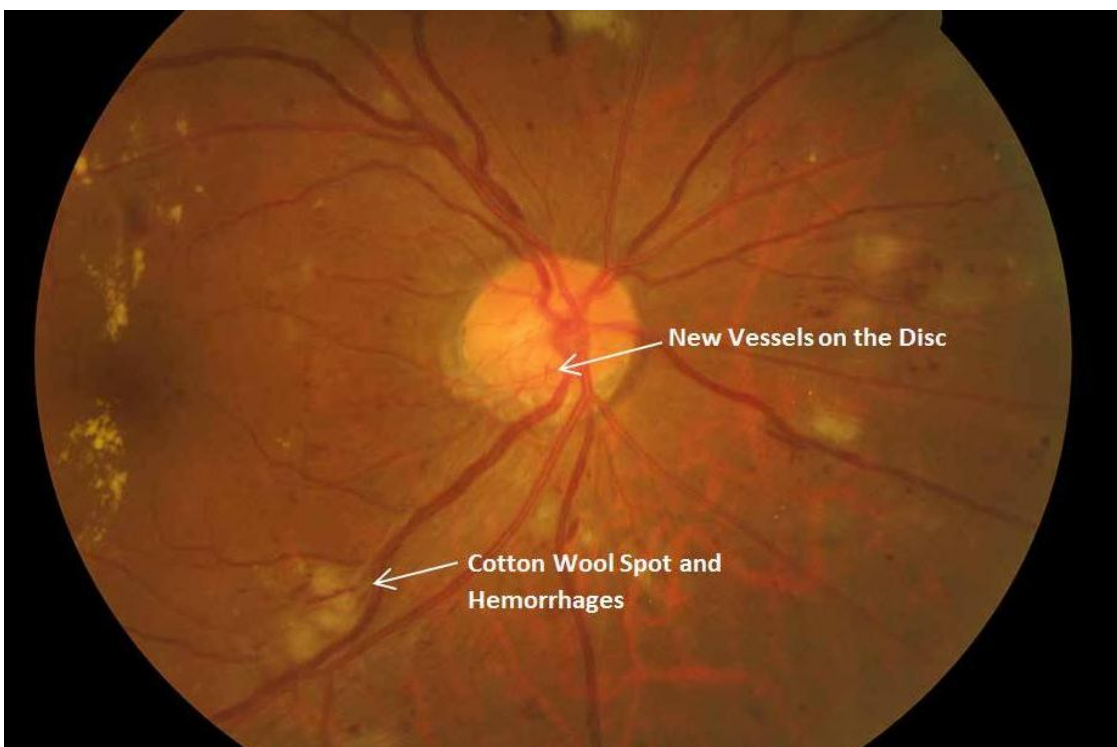


Figure 13: High risk proliferative diabetic retinopathy with new vessels at the disc

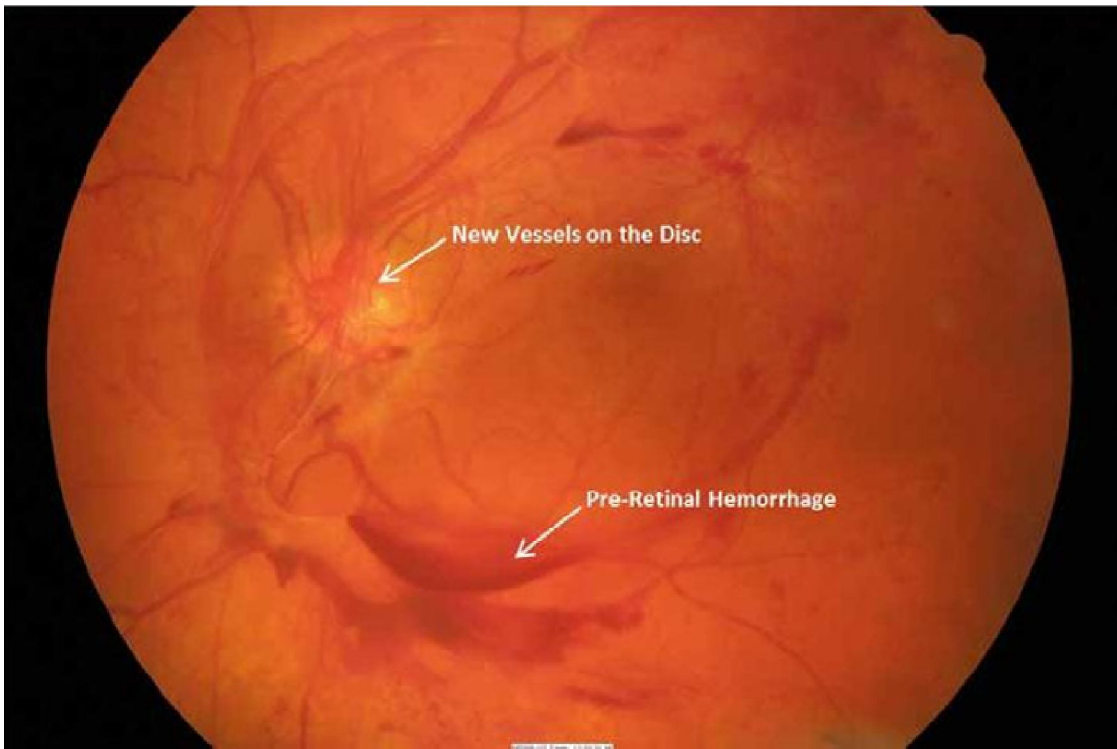


Figure 14a: High risk proliferative diabetic retinopathy. Pre-retinal haemorrhage before with new vessels on the disc.

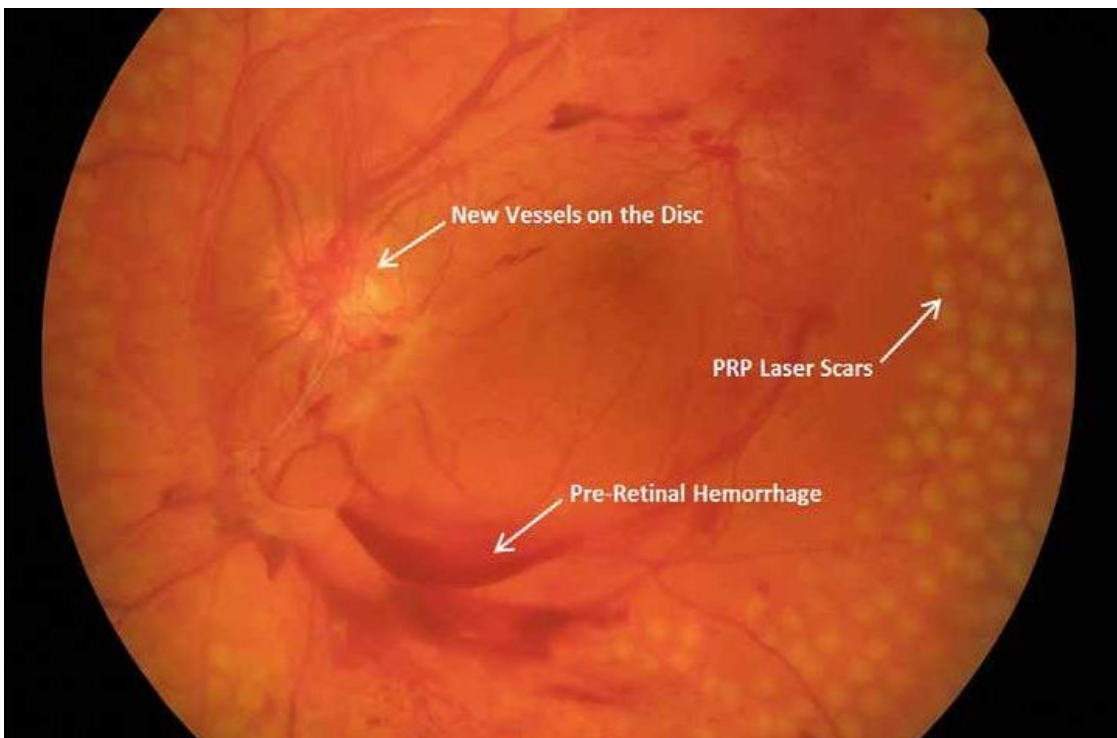


Figure 14b: High risk proliferative diabetic retinopathy, with new panretinal photocoagulation (PRP) scars

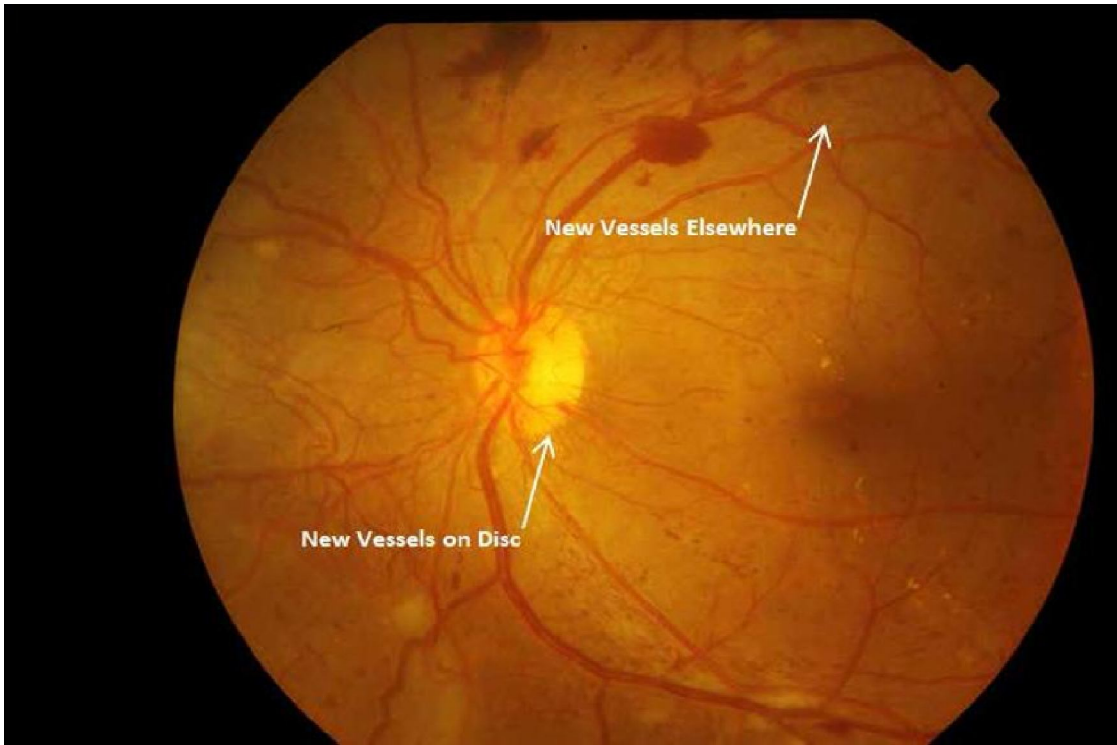


Figure 15a: Proliferative diabetic retinopathy. New vessels on the disc and elsewhere

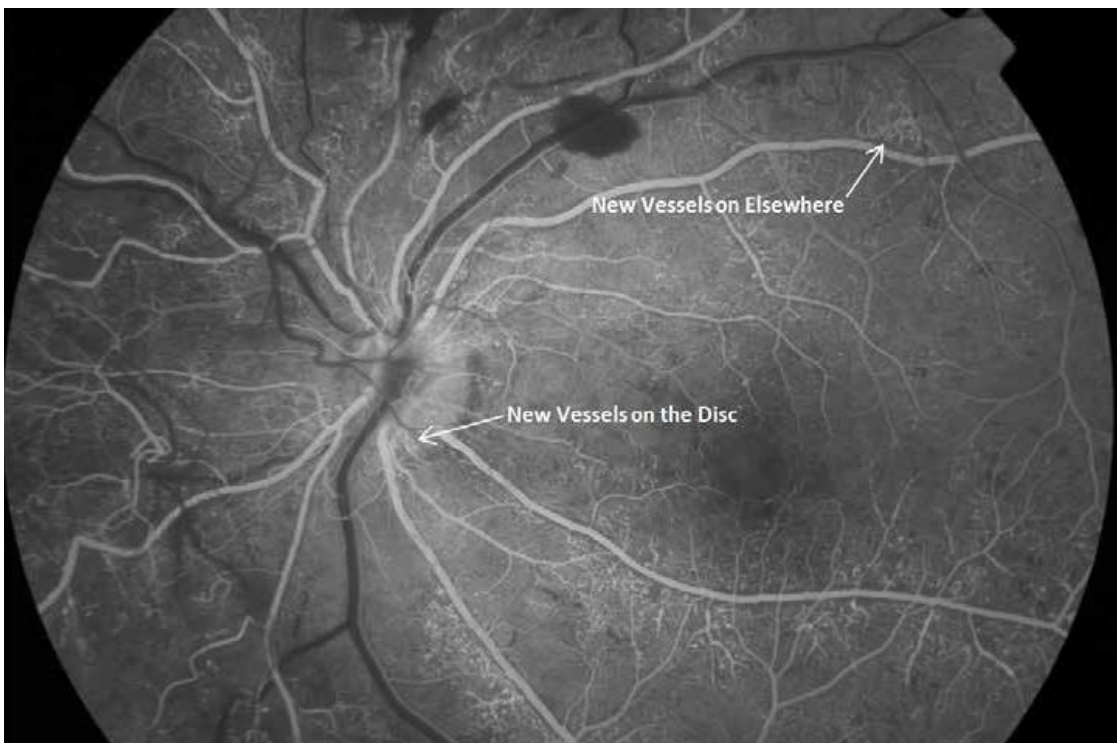


Figure 15b: Proliferative diabetic retinopathy. New vessels on the disc and elsewhere on fluorescein angiogram

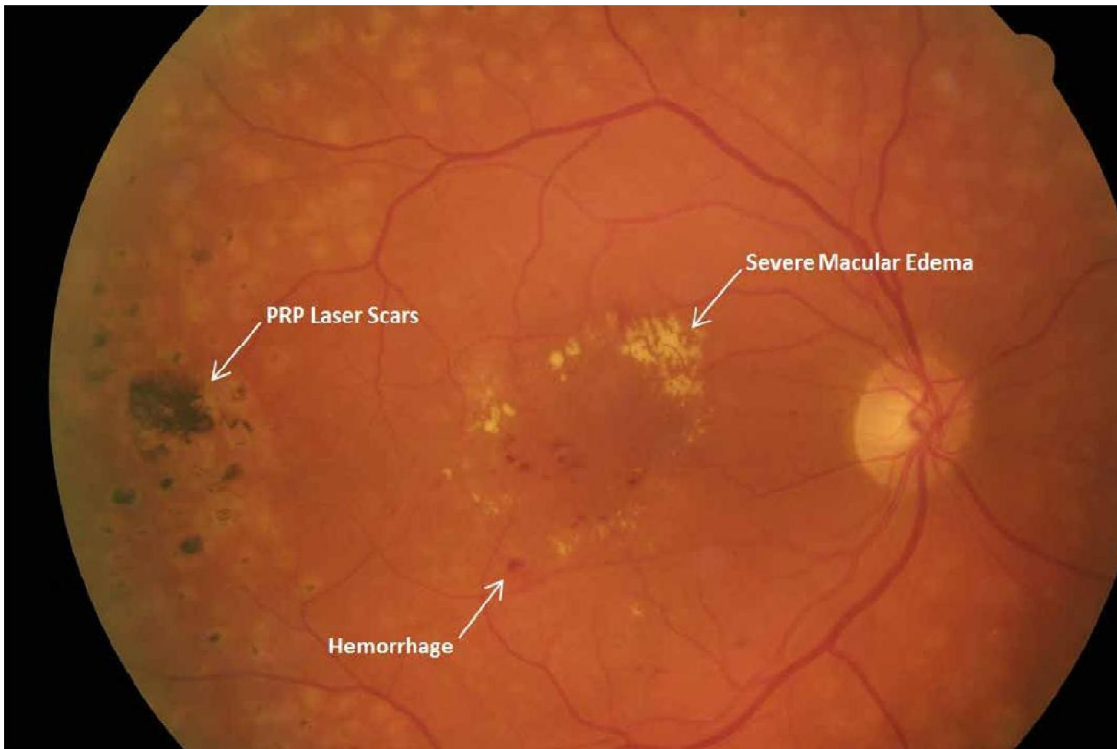


Figure 16a: Diabetic macular oedema with panretinal photocoagulation (PRP) (right eye)

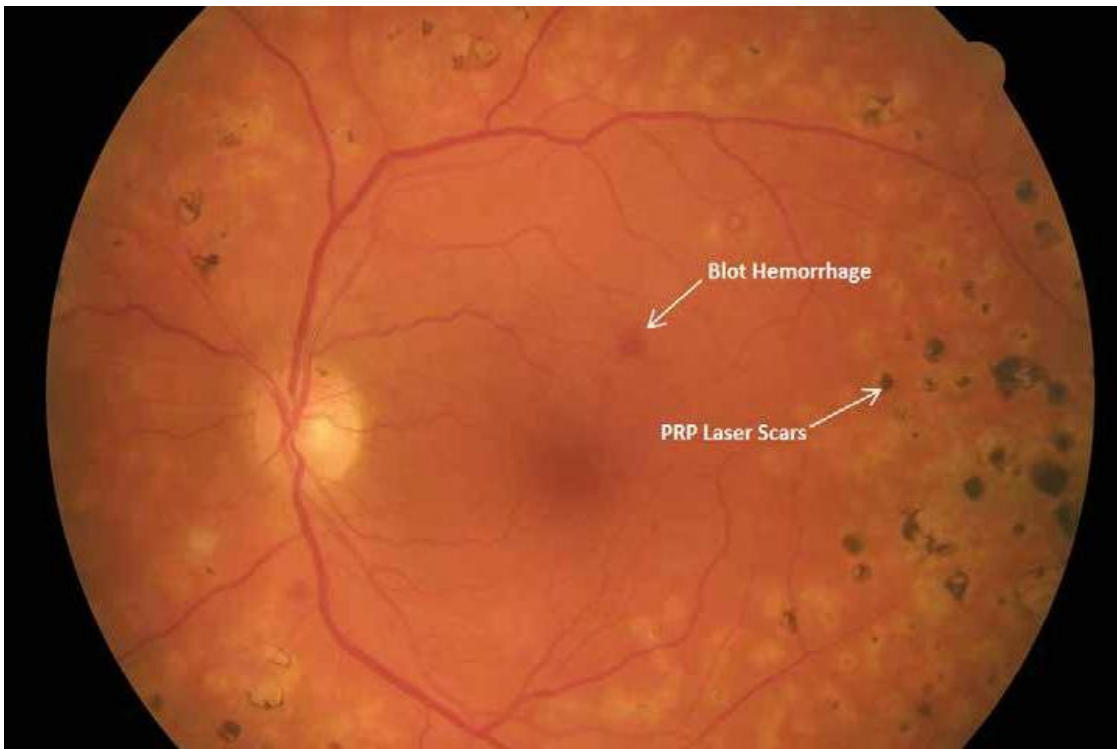


Figure 16b. Diabetic macular oedema with panretinal photocoagulation (PRP). (left eye)

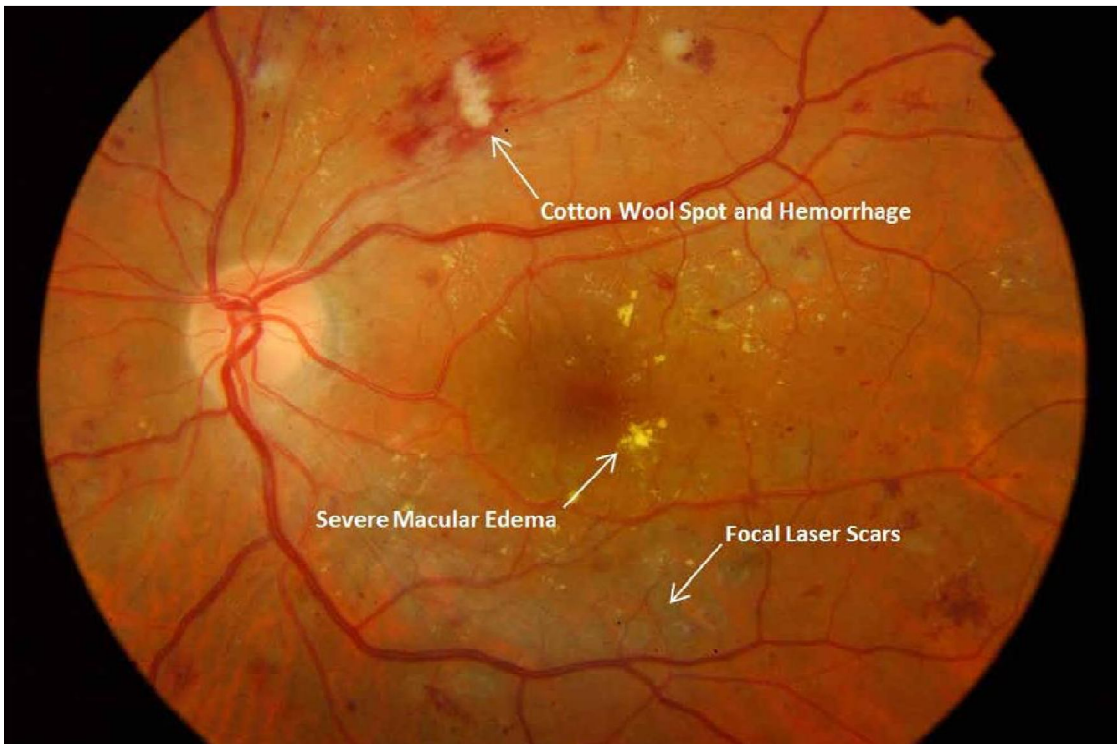


Figure 17a: Persistent diabetic macular oedema after focal laser treatment




Figure 17b: Persistent diabetic macular oedema after focal laser treatment on fundus fluorescein angiogram

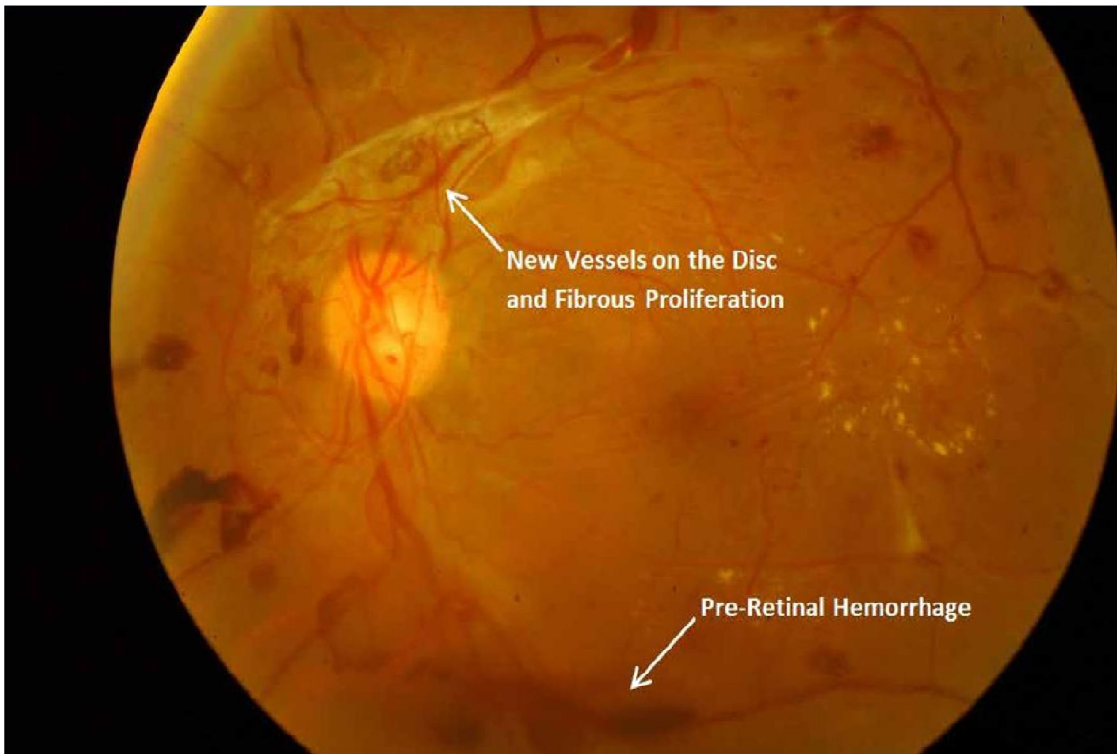


Figure 18a: Proliferative diabetic retinopathy with pre-retinal haemorrhage

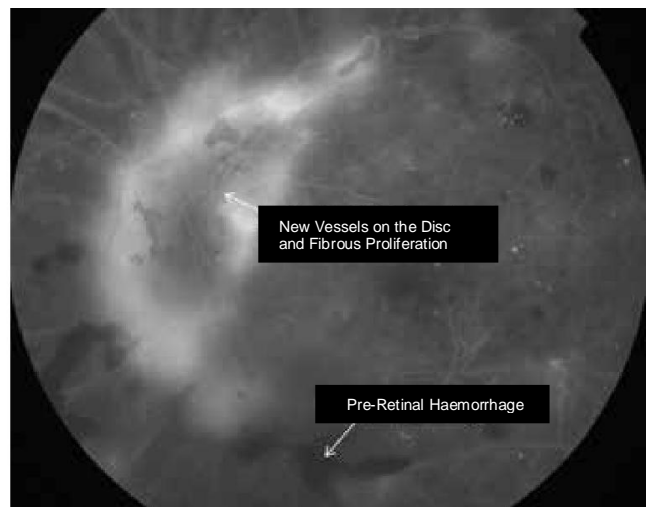
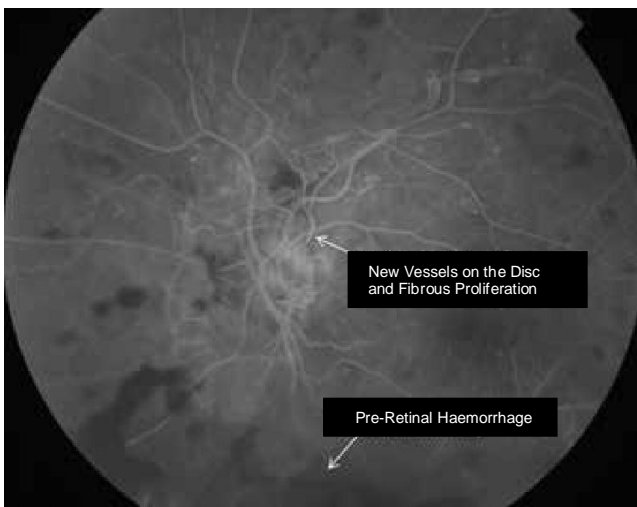


Figure 18b: Proliferative diabetic retinopathy with pre-retinal haemorrhage on fundus fluorescein angiogram

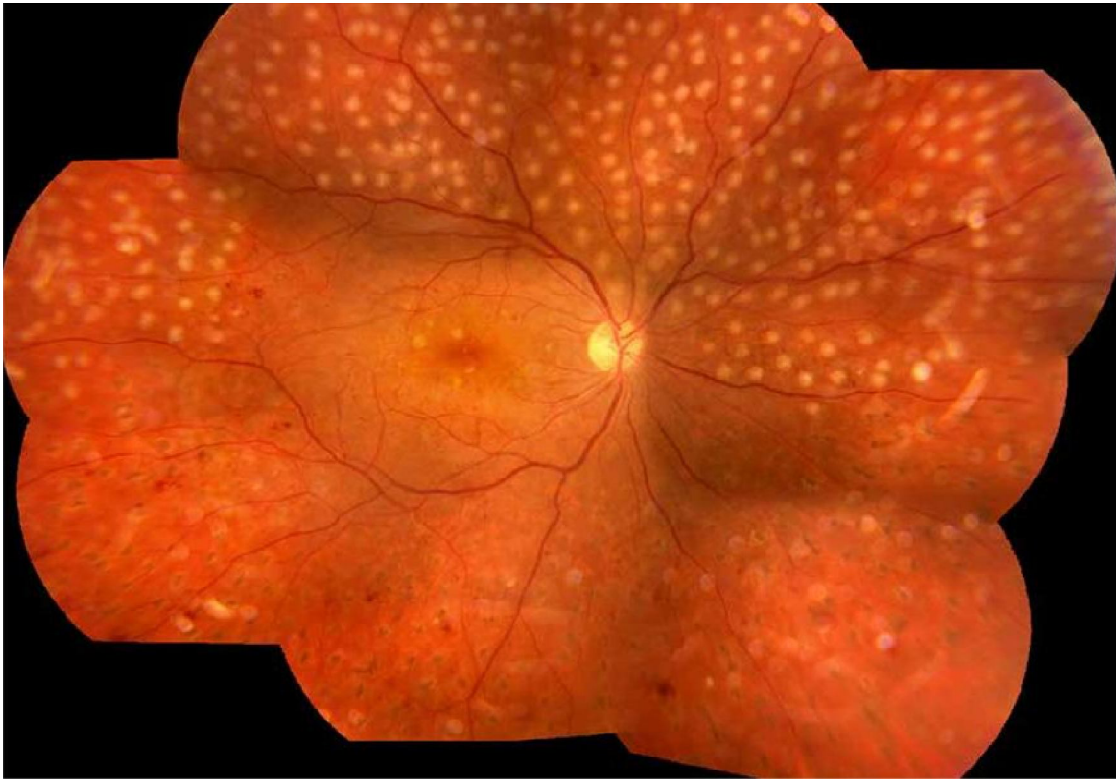

Figure 19: Panretinal (PRP) photocoagulation. First session: inferior retina (laser scars). Second session: superior retina (fresh burns). Third session will be needed to complete PRP.

Credit

Our special gratitude to the International Council of Ophthalmology (ICO) as the VISION 2020 India guidelines have been developed using the guidelines (February 2014) developed by International Council of Ophthalmology. We fully acknowledge the use of the ICO guidelines as the basis for our discussion. Also, we give credit to ICO for allowing us to adapt and use it in the country context.

Acknowledgements

VISION 2020 India expresses its gratitude towards all the prominent participants of DR consultation who supported in developing the guideline with their expert inputs.

We are thankful to Divyajyoti Trust for playing a key role in coordinating the consultation to make it a successful one and also for drafting the guidelines.

We are very thankful to Orbis India for their financial support without which this consultation could not have been done.

We are grateful to Venu Eye Institute for hosting the consultation. We are thankful to all the experts who gave their valuable time and expertise to support in the development of the guidelines.

We also look forward for the same enthusiasm and support in future from the esteemed members of VISION 2020: The Right to Sight-INDIA.

NOTE:

These guidelines have been developed using the existing International Council of Ophthalmology (ICO) guidelines of February 2014. These draft guidelines are for circulation within the VISION 2020: The Right to Sight-INDIA members for their use and other institutions/organizations interested. These will be updated on a periodic basis following inputs from the users. The revised guidelines, following further consultations, will be submitted to the National Program for Control of Blindness (NCPB), Ministry of Health and Family Welfare, Government of India for adoption as national guidelines.

VISION 2020: The Right to Sight-INDIA

VISION 2020: The Right to Sight – India is a national forum for eliminating avoidable blindness by year 2020. It is a key driver of the World Health Organisation (WHO) and International Agency for the Prevention of Blindness (IAPB) joint global initiative for eliminating avoidable blindness.

It is a collaborative effort of, INGOs, NGOs, eye care organisations in India and the Government to coordinate and advocate for improved eye care programs; gaining and sharing knowledge and think solutions together to achieve quality, comprehensive and equitable eye care.



<i>Supported by</i>	<i>Process led by</i>	<i>Consultation Hosted by</i>
Orbis	Divyajyoti Trust	Venu Eye Institute & Research Centre
		

VISION 2020: The Right to Sight – INDIA
2nd Floor, D- 21, Corporate Park,
Sector -21, Near Sector 8 Metro Station,
Dwarka, New Delhi – 110 078, INDIA

